



SURGICAL ANATOMICAL APPROACH OF THE ABDOMEN IN THE GOAT

A Thesis

Presented to the Graduate School

Faculty of Veterinary Medicine, Alexandria University


In Partial fulfillment of the Requirements for the Degree

Of

Doctor of Philosophy in Veterinary Sciences

In

(Anatomy)



By

Samir Ahmed Awad Elgendy

May (2007)

**SURGICAL ANATOMICAL APPROACH
OF THE ABDOMEN IN THE GOAT**

Presented by

Samir Ahmed Awad Elgendy

For the degree of

Doctor of Philosophy in Veterinary Sciences

In

Anatomy

Examiners' Committee:

Approved

Prof. Dr. Abd Alla Hifny Taha

Prof. of Anatomy and Embryology

Faculty of Veterinary Medicine Assiut University

Prof. Dr. Ali Abdel Kader Tolba Mansour

Prof. of Anatomy and Embryology and the Dean

of faculty of Veterinary Medicine Kafr Elsheikh University

Prof. Dr. El-Said Eissa

Prof. and Head of Anatomy and Embryology

Department Faculty of Veterinary Medicine

Alexandria University (Advisor)

Prof. Dr. Mohamed El-Said Amin

Prof. of Anatomy and Embryology

Faculty of Veterinary Medicine Alexandria University (Advisor)

Prof. Dr. Rafat Mohamed Ahmed El-Bakary

Prof. of Anatomy and Embryology


Faculty of Veterinary Medicine Alexandria University (Advisor)

Date: 16/5/2007

Advisor's Committee:

Prof.Dr. El-Said Eissa

Prof and Head of Anatomy and Embryology Department
Faculty of Veterinary Medicine Alexandria University



Prof.Dr. Mohamed El-Said Amin

Prof. of Anatomy and Embryology Faculty of Veterinary
Medicine Alexandria University



Prof.Dr. Rafat Mohamed Ahmed El-Bakary

Prof. of Anatomy and Embryology Faculty of Veterinary
Medicine Alexandria University



ACKNOWLEDGMENT

First and foremost, all thanks are due to **ALLAH**, The most beneficent and merciful.

I would like to express my heartily thanks for **Prof. Dr. E. E. Enany** Prof. and Head of Anatomy and Embryology Department, Faculty of Veterinary Medicine, Alexandria University for his kind supervision, generous attitude, continuous support and help.

I am greatly indebted and express my sincere gratitude to **Prof. Dr. M. E. Amin** Professor of Anatomy and Embryology, Faculty of Veterinary Medicine, Alexandria University for his sincere guidance, continuous encouragement and help, and continuous interest and valuable advises throughout this work.

My deepest gratitude and faithful thanks to **Prof. Dr. R. M. El-Bakary**, Prof. of Anatomy and Embryology ,Faculty of Veterinary Medicine. Alexandria University for his guidance, continuous interest and valuable advises throughout this work.

My deepest thanks to, **Dr. A. Elsharaby, Dr. M. Elsafy, Dr. Sh. Hafez and Dr. M.H. Elkamar**, for their cooperation and for their kindness, continuous interest and valuable advises throughout this work.

Finally I wish to extend my appreciation to **Dr. M. Abu Mandour** for his continuous support and help, and to all staff member and workers of the Department of Anatomy and Embryology Faculty of Veterinary Medicine, Alexandria University.

Contents

	Page
Introduction	1
Review of Literature	2
• I. The Abdomen	2
• II. Abdominal cavity	3
• III. Abdominal organs	12
• IV. Surgical approach of the abdomen	22
Material and Methods	24
Result	26
I. The Abdomen	26
II. Abdominal Cavity	26
III. Abdominal Organs	35
IV. Cross sectional anatomy of the abdomen	43
V. Computed tomography of the abdomen	44
VI. Surgical approach of the abdomen	46
Discussion:	103
• I. Abdomen	103
• II. Abdominal cavity	103
• III. Abdominal organs	110
• IV. Surgical approach of the abdomen	113
Summary	118
Conclusion	120
References	121

LIST OF FIGURES

Fig. (1): The ventral view of the abdomen of the buck showed, the topographic regions of the abdomen.	49
Fig. (2): Lateral view of the abdomen of goat, explained the paralumbar fossa:	50
Fig. (3): Superficial dissection of the abdominal wall of the goat (Left lateral view).	51
Fig. (4): Superficial dissection of the abdominal wall of the buck (ventrolateral view).	52
Fig. (5): Right view of the abdominal wall of the goat.	53
Fig. (6): Enlarged part of external rectus sheath at the epigastric region, show the arrangement of the aponeurosis of external and internal abdominal oblique muscles.	54
Fig. (7): Left lateral view abdominal wall in the goat explained the abdominal muscle.	55
Fig. (8): Lateral view of abdominal wall of goat explained its arteries and nerves.	56
Fig. (9): Ventral view of the abdominal wall.	57
Fig. (10): Right lateral view the abdominal wall of goat explained its vein	58
Fig. (11): Ventral view abdominal wall explain its vein drainage.	59
Fig. (12): Abdominal cavity (caudal part):	60
Fig. (13): Caudal view the diaphragm.	61
Fig. (14): Left lateral view of the thorax and abdomen showed, the costal attachment of the diaphragm by the dotted line.	62
Fig. (15): Left lateral view of the abdomen of the goat	63
Fig. (16): Left lateral view explained the topography of the abdominal organ of the goat (omentum was removed)	64

Fig. (17): Left lateral view of the abdomen explained the abdominal organs in goat which was fasted 48 hrs	65
Fig. (18): The left lateral view explained the topography of the abdominal organs (Rumen was reflected):	66
Fig. (19): Right lateral view of the abdomen. 67	
Fig. (20): Right lateral view of the abdomen explained the topography of the abdominal organs.	68
Fig. (21): Right lateral view of the abdomen , showed the topography of the abdominal organ (Removed greater omentum).	69
Fig. (22): The ventral view of the abdomen, explained the abdominal organs of the goat.	70
Fig. (23): Right lateral view of the abdomen explained the topography of the liver. 71	
Fig. (24): Spiral colon show the special arrangement of the centripetal and centrifugal gyri.	72
Fig. (25): Right lateral view of the pelvis and abdomen explained the topography of the abdominal and pelvic organs in the pregnant goat (4 months).	73
Fig. (26): Lateral abdominal radiograph of the goat gastrointestinal tract after 20 minutes of barium administration.	74
Fig. (27): Lateral abdominal radiograph showed the position the various of the goat gastrointestinal tract after 1 hrs of barium administration.	75
Fig. (28): Ventrodorsal view of abdominal radiograph explained goat stomach after 1 hrs of barium administration.	76
Fig. (29): Lateral abdominal radiograph showed the position of the various part of the goat gastrointestinal tract after 4 hrs of barium administration.	77
Fig. (30): The ventrodorsal view of abdominal radiograph showed the position of the gastrointestinal tract of goat after 24 hrs of barium administration.....	78
Fig. (31): Lateral abdominal radiograph showed the position of gastrointestinal tract of the goat at 24 hr of barium administration.	79
Fig. (32): Right view of the abdominal cavity showed the celiac artery.	81
Fig. (33): Right view of the abdominal cavity showed the celiac artery.	82

Fig. (34): Right lateral of intestine explained the cranial mesenteric artery.	83
Fig. (35): Right lateral view of goat stomach explained their celiac lymphocenter.....	84
Fig. (36): Right lateral view of abdomen explained the cranial mesenteric lymph center.	85
Fig. (37): Cross sectional anatomy of the cranial abdomen of the goat showed stomach compartment, liver, spleen and pancreas.	86
Fig. (38): Cross sectional anatomy of goat middle abdomen.	87
Fig. (39): Cross sectional anatomy of the goat caudal abdomen.	89
Fig. (40): Axial-images of the computed tomography of the goat, cranial abdomen, showed the stomach compartment livers spleen and pancreas (B & F) lung windows.	91
Fig. (41): Axial images of the computed tomography of the goat middle abdomen.	93
Fig. (42): Axial images of the computed tomography of the goat caudal abdomen.	95
Fig. (43): Cross sectional anatomy of three months abdomen of immature goat. ..	97
Fig. (44): Left Lateral view of the abdomen of goat, explained the sites of the surgical approach of abdomen.	99
Fig. (45): Right Lateral view of the abdomen of goat, explained the sites of the surgical approach of abdomen.	100
Fig. (46): The surgical approach to the rumen (A) kidneys (B & D) spleen (C) gall bladder (E) and intestine (F).	100

INTRODUCTION

Ruminant Anatomy has traditionally focused on the bovine model with limited reference to comparative anatomy of the small ruminant. The goats are often considered as being anatomically minimally different from the bovine, so that, we focus on the studies to topography of the abdominal wall and organs till give easy approach to the abdominal organs.

Clinicians and surgeons of the veterinary medicine spend a great deal time of examining the abdomen, particularly in auscultation and palpation to the goat stomach. There are also other diagnostic procedures such as percussion of the liver, spleen and take biopsy from liver and spleen and sampling the abomasum and gall bladder contents. In addition to that the surgeons attend approach any abdominal organs with easy technique and avoiding the main blood vessels. So that all of these techniques both diagnostic and surgical require working and knowledge about the topographic anatomy of the abdominal wall and organs.

The uses the X-ray with contrast media are helpful in the studying of the structures and function of the gastrointestinal tract as well as diagnosing the diseased condition. The computed tomography (C.T) and a cross sectional anatomy give the normal topography of the abdominal organs.

The purposes of the present Studies are;

1. Studying the abdominal wall; muscles, blood vessels and nerves till help the veterinarians during their clinical work either nerve block or surgical approach.
2. Observation the normal anatomical pattern of caprine abdominal organs with different diagnostic tools as X-ray and C.T.
3. Establishment the base of C.T. image of abdomen referring to their normal cross-section anatomy.
4. Establishment the basic for surgical approach to each abdominal organ in the goat, from the normal studies to abdominal wall and organs.
5. How to use the normal anatomical pattern to apply on the live animal to establish the most clinical application of the abdomen in goat

REVIEW OF LITERATURE

I- The abdomen:

In domestic animals, **Nickel, Schummer and Seiferle (1973)** mentioned that the abdomen is the part of the trunk that extends from the costal arch and the last rib to the linea terminals. This segment of the trunk contains the abdominal cavity. **Small Wood (1992)** in domestic animals added that the abdominal cavity lies cranial to the costal arch is thus protected by the thoracic cage, this portion is named an intrathoracic part of abdominal cavity. The lateral part of the abdominal wall that is not protected by rib cage, pelvis or thigh called the flank. Both **Garrett (1988)** in the goat and **Small Wood (1992)** in ruminants described that the paralumbar fossa is triangular depression in the upper part of the flank, it is especially prominent in the standing ruminant and it is an important surgical area. It is bounded dorsally by the transverse processes of the lumbar vertebrae from L2 to L5, cranially by the last rib and caudoventrally by the tension ridge created by the weight of the abdominal viscera on the ventral part of the internal abdominal oblique muscle.

Dyce; Sack and Wensing (2002) in the ruminant described that, the form of the abdomen varies with age, obesity and physiological condition. In adult it is both deep and wide and the floor, which dips behind the sternum, ascends very steeply in its caudal to join the pubic brim, while in the young calf the abdomen is shallower and laterally compressed, and the floor slopes gradually to pelvis. The abdomen is usually bilaterally symmetrical, although advanced pregnancy or excessive distention of rumen may cause one side to bulge more markedly.

EL Hagri (1967) in domestic animals revealed that the abdomen is divided by two transverses imaginary planes; the first passes at the last thoracic vertebra and second at the tuber coxae. They divide the abdomen into three large regions; cranial, middle and caudal abdominal regions and by two sagittal planes pass through the middle of inguinal ligament, the abdomen divides into nine regions

Abd Elmoien (1995) in the goat mentioned that the transverse processes of the lumbar vertebrae in addition to tuber coxae are well marked. **May (1977)** in the sheep mentioned that the scare of umbilicus lies in a transverse plane through the third lumbar vertebra.

II .Abdominal cavity

EL Hagri (1967) in domestic animals revealed that the abdominal cavity is bounded ventrally by the abdominal straight muscle, the internal and external abdominal oblique muscles, and the abdominal transverse muscle. Laterally by the fleshy parts of these muscles, the cranial parts of two ilia and iliacus muscle, the asternal cartilages of the ribs, and the parts of ribs below attachment of the diaphragm. Dorsally by lumbar part of the vertebral column, the crura of the diaphragm and sublumbar muscles. The cranial wall is formed by the diaphragm and caudally by linea terminals.

II.A. Abdominal wall

The ventral and lateral walls of the abdomen are composed of nine or ten layers although not all cover the entire extent, it have reported by **Dyce et al. (2002)** in ruminant.

A.1-The layers of ventrolateral abdominal wall.

1- Skin

Sisson (1975) in the ox mentioned that the skin is thicker than that of any of other domestic animals. **Dyce et al, (2002)** in the dog and horse reported that the skin thicker over the flank but thin ventrally especially on the cleft between the abdomen and the thigh.

2- Superficial abdominal fascia:

Getty (1975) in the ruminant stated that the superficial fascia of abdomen is in part, fused dorsally with thoracolumbar fascia; cranially, it is continuous with superficial fascia of the shoulder and arm, and caudally, with that of gluteal region. In inguinal region it forms parts of the fascia of the penis or the mammary gland. At the ventral part of the flank it forms a fold which is continuous with the fascia of thigh near the stifle joint. **Nickel et al. (1986)** in ruminant added that the fascia of trunk can blend with thoracolumbar fascia in dorsal and lumbar regions and several areas detach slips which find insertion on free ends of thoracic and lumbar spinous processes.

Dyce et al. (2002) in ruminant observed that the fascia provides path way for the cutaneous nerves and encloses the elongated subiliac lymph nodes lies vertically within the skin fold at the cranial margin of thigh some distance above patella, a number of smaller nodes within paralumbar fossa and presence of the subcutaneous abdominal vein runs forward over the abdominal floor from the udder, also it contains cutaneous trunci muscle.

3- Cutaneous trunci muscle.

Abd Elmoien (1995) in the goat observed that the cutaneous trunci muscle originates from the superficial layer of the thoracolumbar fascia. The muscle fibers continue cranially by a thin aponeurosis of about 4 to 5 cm with the M. omobranchialis, the fleshy portion of muscle is separated dorsally by a wide increasing space as traced caudally. Ventrally it communicates with its fellow of the opposite side along lateral border of M. preputialis cranialis or M. supramammarius. While **Getty (19975)** in ruminant denoted that the cutaneous trunci muscle arises from the interbrachial fascia on the medial surface of the arm, elbow and the fascia on the lateral aspect of shoulder and it terminates on the deep layer of the skin near the middle of the back.

Moreover **Dyce et al. (2002)** in ruminants added that the cutaneous trunci muscle is thick over the lower part of the flank but thins dorsally and doesn't extend over the paralumbar fossa. It also leaves the abdominal floor bare except for detachable fascicles that supply the male animal with the cranial and caudal muscles of the prepuce. The cutaneous muscle extends through flank fold to end in an aponeurosis over the lateral surface of the thigh. **Smuts and Bezuidenhout (1987)** in camel mentioned that the cutaneous trunci muscle is absent.

4. Cranial preputial muscle.

Getty (1975) in the ruminant mentioned that the cranial preputial muscle arises from the fascia slightly caudal to the xiphoid cartilage, numerous fascicles course caudally to converge about the preputial orifice and some fibers pass to caudolateral surface of prepuce. **May (1977)** in the sheep said that they are thin flattened bands arising close together in the xiphoid region and passing caudally around the umbilicus to unite immediately behind the preputial orifice.

5. Caudal preputial muscle.

Abd Elmoien (1995) in the goat observed that the caudal preputial muscle is a long muscular fascicle detached from the cranial end of the tuber ischii in common with fibers of the semimembranosus muscle by 2 to 3 narrow tendons. It preceded forward lateral to the cremaster muscle and terminates at the cranial part of the prepuce. While **May (1977)** in the sheep denoted that it arises cutaneously cranial to the neck of scrotum and converge towards the dorsal of preputial bulb. They are about 18 to 20 cm long and 0.5 cm wide occupying the position in the fat and connective tissue between penis and abdominal wall.

6. Supramammary muscle.

Smuts and Bezuidenhout (1987) in the she-camel described that the supramammary muscle as a flat muscle of about 15 cm. long which is directed caudally to terminate on the base of the udder just above the caudal teats. **Evans and Delahunta (1988)** in the bitch mentioned that it is paired, arising caudal to the xiphoid cartilage, extends caudally in loose bundles over the mammary gland complex to the pubic region and cranial to the inguinal mammary glands. Each blends with the cutaneous trunci muscle.

7. The flava abdominal tunic

Both **May (1977)** in the sheep and **Garrett (1988)** in the goat stated that the deep fascia of the abdominal wall forming the abdominal tunic flava which consist of the elastic tissue and a variable amount of fat and covers the external abdominal oblique muscle and its aponeurosis, it is better developed ventrally than dorsally, in the mid-ventral line, it is attached to the linea alba, whilst deeply it is difficult to separate from the external oblique aponeurosis and assist in the formation of the external opening of the inguinal canal. Laterally, it can be separated from the underlying structure with more ease; it forms the medial suspensory ligament of the udder of the ewe or the deep fascia of the prepuce and tunica dartos of the scrotum of the ram. In addition to that **Getty (1975)** in the ruminant mentioned that the lamellae of the abdominal tunic penetrate the external abdominal oblique muscle to attach to the bony rib cage. It also has an attachment to the tuber coxae.

8. External abdominal oblique muscle.

May (1977) in the sheep described that the origin of external abdominal oblique muscle is from the costal wall from the ventral part of the fifth rib to slightly dorsal to middle of the last rib and from the lumbodorsal fascia near the end of the transverse processes of the lumbar vertebrae. The direction of muscle fibers varies; those in costal region are mostly transverse, whilst in the upper flank they run longitudinally. The muscle fibers don't reach the lumbar transverse processes or the tuber coxae. While **Getty (1975)** in ruminant and **Smuts and Bezuidenhout (1987)** in camel reported that the external abdominal oblique muscle originates from the sixth to last rib, in addition to fascia over the intercostal muscles in ruminant and the thoracolumbar fascia in camel.

Moreover **Getty (1975)** in ox added that, the muscle fibers in the flank region don't reach the tuber coxae, in contrast to the goat where it reaches this tuber. However **Nickel et al. (1986)** in ruminant mentioned that the origin of the costal part appear as digitations which extend from under border of the latissimus dorsi muscle behind the ventral serratus muscle and reach as far forward as the 4th or 5th ribs. The lumbar part is relatively small and takes origin from the last rib and thoracic lumbar fascia.

Getty (1975) in ruminant and **May (1977)** in the sheep mentioned that the insertion of external abdominal oblique muscle is by an aponeurosis to the linea alba, prepubic tendon and tuber coxae. This aponeurosis blends with underlying aponeurosis of internal oblique muscle. Moreover **Sisson (1975)** in the horse mentioned that the insertion of external abdominal oblique muscle is by aponeurosis to the linea alba, prepubic tendon and tuber coxae, in addition to the femoral lamina that pass to the medial aspect of the thigh blending with the femoral fascia in addition to a thin iliac lamina attached to the lateral border of ilium. **May (1977)** in the sheep revealed that the caudal edge of the aponeurosis of the external abdominal oblique muscle is thickened to form the inguinal ligament between the tuber coxae and prepubic tendon.

Abd Elmoien (1995) in the goat observed that the external abdominal oblique muscle terminates by abroad thin glistening aponeurosis. In both epigastric and mesogastric regions, the medial crus extended caudoventrally for a short distance to be interwoven and over crossed by those of internal abdominal oblique muscle, it continues its course to the midventral line deep to the internal abdominal oblique aponeurosis. In the hypogastric region the external abdominal oblique aponeurosis continued caudoventrally superficial to that of internal abdominal oblique up to the midventral line. Moreover **Rizk (1980)** in the kangaroo observed that the external abdominal oblique aponeurosis of one side is directed continuous with superficial fiber the M. rectus abdominis of the opposite side.

9. The internal abdominal oblique muscle

Abd Elmoien (1995) in the goat and **May (1977)** in the sheep revealed that the internal abdominal oblique muscle arises from the tuber coxae, a dorsal part of the inguinal ligament and thoracolumbar fascia and the former added that from the thoracolumbar fascia by the very thin aponeurosis on a level of the last lumbar vertebra. While, **Dyce et al. (2002)** in ruminants described that, the different origin arises from the transverse processes of the lumbar vertebrae, tuber coxae and lateral crus of external abdominal oblique aponeurosis. **Getty (1975)** in ruminants and **May (1977)** in the sheep mentioned that the aponeurosis of this muscle is divided into two parts the smaller dorsal part is inserted into caudal border of the last rib and its cartilage by a thin aponeurosis in ruminants and to last three or four ribs along the costal arch by three or four a thin aponeurosis in sheep. Both **May (1977)** in the sheep and **Abd Elmoien (1995)** in the goat mentioned that the muscle fibers directed cranioventrally by a broad thin aponeurosis which fused with that of external abdominal oblique muscle to form the outer lamina of rectus sheath.

Both **Rizk (1980)** in bovidae and **Rizk (1984)** in the monkey reported that the internal abdominal oblique aponeurosis emerges superficial to that of external abdominal oblique muscle near the lateral border of the rectus abdominal muscle. At the mid ventral

line it becomes directly continuous with the opposite external abdominal oblique aponeurosis

10. straight abdominal muscle (rectus abdominal muscle)

May (1977) in the sheep mentioned that the rectus abdominal muscle arises from the lateral border of sternum as far cranial as the 3rd costal cartilage and there are four or five transverse tendinous intersections. **Raghavan and Kachroo (1964)** in the ox revealed that it originates from the 3rd or 4th costal cartilages and terminate by the prepubic tendon into the pecten ossis pubis and two lateral branches to the iliopubic eminence in addition to the strong fibrous attachment to the pelvic symphysis. **Smuts and Bezuidenhout (1987)** in the camel mentioned that the rectus abdominal muscle arises from the last sternebra and the costal cartilages of the 7th and 8th ribs and become tendinous before its attachment to the pecten pubis. **Habel and Klaus (1992)** in the ruminant observed that the rectus abdominal muscles become abruptly narrower as they approached the inguinal region and turned their inner surface toward each other, forming in the cow a narrow median trough. Around depression about 4 cm in diameter is seen in the median plane at the junction of tendons of the recti and aponeurosis of the internal oblique. This tendinous pit is usually filled with retroperitoneal fat. The caudolateral border of rectus extended to the cranial border of the deep inguinal ring.

11. Transverse abdominal muscle

May (1977) in the sheep and **Delahunta and Habel (1986)** in ruminant mentioned that the transverse abdominal muscle has a fleshy origin from the ventral ends or cartilages of the asternal ribs and tendinous origin from the lumbar vertebrae. Moreover **Abd Elmoien (1995)** in goat revealed that it originates by tendinous fibers from the medial aspect of the costal arch, caudal border of distal third of the last 4th ribs. Its lumbar origin is by thin aponeurosis from the transverse processes of the first five lumbar vertebrae. The muscle fibers run distally toward the midventral line along the abdominal wall. They increased in length as traced caudally. While **Beaver (1980)** in the ruminant stated that the origin of transverse abdominal muscle arises from costal arch and lumbodorsal fascia.

Small Wood (1992) in ox mentioned that the transverse abdominal muscle in area of the paralumbar fossa is aponeurotic part, so that any surgical incision in paralumbar fossa does not involve cutting the transverse muscle proper. **Getty (1975)** in ruminant revealed that the aponeurosis of the transverse abdominal muscle passes completely deep to rectus abdominal muscle forming the inner lamina of the rectus sheath, **Abd Elmoien (1995)** in the goat denoted that, the fibers of the caudal portion of the transverse aponeurosis proceeds distally for about 1 to 2 cm to be splitted into a superficial and deep layers.

Inguinal canal

Abd Elmoien (1995) in the goat and **Getty (1975)** in ruminant mentioned that the superficial inguinal ring is disposed between both crura of the external abdominal oblique aponeurosis and measures about 3.5 cm to 4 cm. in length in goat. While **Ahmed et al. (1985)** in the rabbit, it is situated between the fleshy and aponeurotic portions of that muscle. **May (1977)** in the sheep added that the abdominal tunic assist also in its formation. **Getty (1975)** in the ruminant observed that the deep inguinal ring is presented between internal oblique abdominal muscle and the inguinal ligament. Moreover **Nickel et al. (1986)** in ruminant added that the rectus abdominal muscles sharing in its boundary. While **Ahmed et al. (1985)** in the rabbit mentioned that it is found between the internal abdominal oblique

and rectus abdominal muscles. **Getty (1975)** in the ruminant observed that the inguinal canal is bounded caudolateral by the inguinal ligament and the lateral crus of aponeurosis of the external abdominal oblique muscle and craniomedially is bounded by the caudal portion of the internal abdominal oblique muscle.

May (1977) in the sheep added that the caudomedial wall is formed by the prepubic tendon and transverse fascia also observed that the inguinal canal contains the cremaster muscle, external pudendal artery and vein, lymph vessels, the genitofemoral nerve and branch of ilioinguinal nerve, tunic vaginalis and the spermatic cord in ram while in the ewe the same blood vessels, nerve and lymph in addition to a small extension of the vaginal process.

A.2. Arterial supply of the abdominal wall.

1. Cranial epigastric artery;

All the available literatures revealed that the cranial epigastric artery is the medial terminal branch of the internal thoracic artery. Both **Ghoshal (1975)** and **Schummer, Wilkens, Vollmerhaus and Habermehl (1981)** in ruminants revealed that the cranial epigastric artery gives the cranial superficial epigastric artery and continues as the cranial epigastric artery which was called the cranial deep epigastric artery, **Hifny, Ahmed and Ibrahim (1984)** in mule observed that, the cranial epigastric artery forms the direct continuation of parent vessel at the level of the caudal border the 8th costal cartilage it passes caudalwards between the 9th costal cartilage and xiphoid process to gain the dorsal aspect of rectus abdominal muscle, it continues within the substance of this muscle and anastomoses with caudal epigastric artery at the umbilical region. On the other hand **Badawi, Ahmed and Saber (1983)** in the camel, reported that there is no anastomoses existed between the cranial and caudal epigastric arteries.

2. Cranial superficial epigastric artery;

Abd Elmoien (1995) in the goat mentioned that the cranial superficial epigastric artery is a slender vessel supplying mainly the cutaneous trunci and the supramammary muscle in the female and the cranial preputial muscle in male in addition to their covering skin. It arises from the lateral aspect of the cranial epigastric artery. It presents between rectus abdominal M. and Transverse abdominal M. then penetrates the former till cutaneous trunci. While **Hifny; Ahmed and Attia (1982)** in the camel considered it as a branch of the internal thoracic artery and added that it gives off an anastomosing branch to the cranial epigastric artery

3. Musculophrenic artery;

Abd Elmoien (1995) in the goat described that the musculophrenic artery is the smaller terminal branch of the internal thoracic artery at the caudal border of the 7th costal cartilage. **May (1977)** in the sheep **Schummer et al. (1981)** in ruminants and **Hifny et al. (1982)** in camel revealed that it begin at the level of the 6th or 7th interchondral space in camel, 7th in ruminants and 8th in sheep, they added that it gives off muscular branches for transverse abdominal muscle and ventral intercostals from 9th to 13th in sheep, 6th to 7th in camel and 6th to 10th in ruminant.

4. The dorsal intercostal arteries

Abd Elmoien (1995) in the goat stated that the dorsal intercostal arteries form the main blood supply of the costal part of the external abdominal oblique muscle from the 7th to the last one. The last three dorsal intercostal arteries terminate in the transverse abdominal muscle. **Hifny et al. (1984)** in the camel observed that from the 8th to the 11th branches cross the costal arch and pierce part of the diaphragm and transverse abdominal muscle to terminate in the rectus abdominal muscle.

5. Dorsal costoabdominal artery

Ghoshal (1975) in the ruminants and **Abd Elmoien (1995)** in the goat stated the dorsal costoabdominal artery is well developed; it is given from the abdominal aorta as the last intercostal artery which runs behind the last rib. **Hifny et al. (1984)** in camel mentioned that it terminates between the transverse abdominal fascia and rectus abdominal muscle. Moreover **Ghoshal (1975)** in ruminant observed that it supplied the transverse, internal oblique and external oblique abdominal muscles.

6. Caudal superficial epigastric artery

Abd Elmoien (1995) in the goat stated that the caudal superficial epigastric artery is a division of the external pudendal artery, it emerge from the superficial inguinal ring in buck, while it is given from the cranial mammary artery in goat. It anastomosis with the cranial superficial epigastric artery. **Schummer et al. (1981)** in ruminants revealed that, it runs toward the umbilicus along the sheath of rectus abdominal muscle where it is situated superficially on the ventral abdominal wall it anastomosis with cranial one at the level of umbilicus.

7. Caudal epigastric artery.

Abd Elmoien (1995) in the goat mentioned that the caudal epigastric artery is detached from the pudendoepigastric trunk. It precedes cranioventrally on the aponeurosis of the caudal portion of external abdominal oblique muscle and deep to the lateral portion of rectus abdominal muscle where it divides into two branches to the last segments. **Ghoshal (1975)** in ruminants mentioned that it courses between the internal abdominal oblique and rectus abdominal muscles, furnishes collateral to both and anastomoses with the cranial epigastric artery inside the rectus abdominal muscle.

8. Deep circumflex iliac artery.

Ghoshal (1975) in the ruminant mentioned that the deep circumflex iliac artery arise from the external iliac artery and divides into cranial and caudal branches, the former furnishes the transverse abdominal, internal and external oblique abdominal muscles, while the caudal branch passes caudoventrally and pierce the abdominal wall. **Hifny; Ahmed and Ibrahim (1981)** in mule observed that the cranial branch of deep circumflex iliac artery divides into dorsal and ventral branches. **Badawi et al. (1983)** in camel mentioned that the deep circumflex iliac artery is represented by two separated vessels cranial branch and caudal branch which originate from external iliac artery. **Saber (1979) and Attia (1980)** in the camel mentioned that each of the end branches of the deep circumflex iliac artery has a separate origin from the external iliac artery

A.3. Venous drainage of the abdominal wall:

1. The cranial epigastric vein:

Abd Elmoien (1995) in goat described that the cranial epigastric vein is one of two terminal branches of the internal thoracic vein at the 7th intercondral space and continuous in the rectus abdominal muscle and anastomose with caudal one at caudal to the umbilicus. It drains the tendinous intersection of rectus abdomens muscle. While **Schummer et al. (1981)** stated that it originated beyond the 7th rib in ox and the 7th or 8th rib in small ruminants.

2. Cranial superficial epigastric vein

Abd Elmoien (1995) in the goat mentioned that the cranial superficial epigastric vein is the direct continuation of cranial epigastric vein as it pierces the rectus abdominal muscle and outer lamina of rectus sheath to subcutaneously seat on the level distal to costochondral junction of 9th rib by about 5 cm. It passes caudal subcutaneously and anastomoses with the caudal one. **Schummer et al. (1981)** in ruminant described that it knows as subcutaneous abdominal vein which passes through the abdominal musculature after its origin from the cranial epigastric vein.

3. Musculophrenic vein:

Abd Elmoien (1995) in the goat stated that the musculophrenic vein is smaller terminal division of the internal thoracic vein emerge at the 7th intercondral space. It ran caudodorsally then crosses the medial aspect of the costal arch between the transverse abdominal muscle and the diaphragm. **Smuts and Bezuidenhout (1987)** in camel mentioned that it drain the costal part abdominal wall.

4. Dorsal intercostal veins:

Abd Elmoien (1995) in the goat mentioned that the dorsal intercostal veins, from the 7th through the last dorsal intercostal vein drained the external oblique abdominal muscle and cutaneous trunci muscle. Three or four dorsal intercostal veins terminate in the transverse abdominal muscle. **Ghoshal et al. (1981)** in domestic animals mentioned that the dorsal intercostal veins descend in the corresponding intercostal space along the costal groove and presents cranial to the artery and nerve.

5. Dorsal costoabdominal vein:

Abd Elmoien (1995) in the goat **Ghoshal et al. (1981)** in small ruminant described that the dorsal costoabdominal vein detaches from left vena azygos by a common trunk with last dorsal intercostal vein at the level of the last thoracic vertebra while **Smuts and Bezuidenhout (1987)** in the camel mentioned that it is detached from right vena azygos.

6. Caudal superficial epigastric vein:

Schummer et al. (1981) in domestic animals revealed that the caudal superficial epigastric vein is a cranial division of the external pudendal vein while **Badawi et al. (1985)** in the buffalo, stated that it is the cranial continuation of the cranial mammary vein. In addition to that **Abd Elmoien (1995)** in the goat stated that the caudal superficial epigastric vein drains the caudal part cutaneous trunci muscle, fascia and skin of the ventral abdominal wall, prepuce and mammary gland.

7. Caudal epigastric vein:

Ghoshal et al. (1981) in ruminants mentioned that the caudal epigastric vein arise from the pudendoepigastric vein, run cranially along dorsal surface of rectus abdominal muscle and enters this muscle and anastomoses with cranial one in umbilicus region. **Yadam (1990)** in the she donkey mentioned that it arises from deep femoral vein and in two cases it originates from the external iliac vein.

8. Deep circumflex iliac vein:

Abd Elmoien (1995) in the goat described that the deep circumflex iliac vein is a single vessels is seen on the either side detaches from common iliac vein and present 3 to 4 cm distal to tuber coxae. **Retting (1969)** in the ox revealed that it is occasionally paired arising on the right side from the caudal vena cava and the left from the common iliac vein or either sides from the caudal vena cava.

A.4. The main nerve supply of the lateral abdominal wall in the ruminants:

Garrett (1988) in the goat **Small Wood (1992)** in ruminants mentioned that the spinal nerves which innervate the paralumbar fossa are T13, L1 and L2. The dorsal branches pass dorsal to the transverse processes of the lumbar vertebrae and ventral branches pass ventral to transverse processes. Both branches must be blocked to perform any surgery in the paralumbar fossa. Moreover **Garrett (1988)** in the goat mentioned that the ventral branches of the lumbar nerves innervate the musculature of the wall, peritoneum and the skin ventral to middle of the paralumbar fossa. The ends of these cutaneous branches may be seen passing through the external abdominal oblique muscle in the ventral part of the paralumbar fossa.

1. The costoabdominal nerve:

Both **Garrett (1988)** and **Abd Elmoien (1995)** in the goat mentioned that the costoabdominal nerve is the ventral division of the 13th thoracic spinal nerve being situated near the caudal surface of the last rib. While **Ghoshal (1975)** in the sheep stated that it is derived from 12th or 13th thoracic spinal nerve. **Garrett (1988)** in the goat added that the costoabdominal nerve passes at the tip of transverse process of 1st lumbar vertebra. Moreover **Abd Elmoien (1995)** in goat added that it is divided into lateral and medial branches caudal to the last rib by 0.5 to 1.0 cm.

2. The iliohypogastric nerve

Abd Elmoien (1995) in the goat and **Smuts et al. (1987)** in camel observed that there are two iliohypogastric nerves; cranial and caudal, the cranial one is the ventral division of the 1st lumbar spinal nerve, while the caudal one is the ventral division of the 2nd lumbar nerve. The two branches divide into a medial and lateral branch. While **May (1977)** in sheep and **Dyce et al. (2002)** in ruminant mentioned that the iliohypogastric nerve is the ventral division of the 1st lumbar nerve which pass under the tip of the transverse process of the 2nd lumbar vertebra.

3. The ilioinguinal nerve:

Abd Elmoneim (1983) in camel and **Abd Elmoien (1995)** in the goat mentioned that the ilioinguinal nerve arises from the ventral branch of third lumbar spinal nerve. The latter added that the ilioinguinal nerve is divided into cranial and caudal branches. The cranial one

is divided into a lateral and the medial branches. **Raghavan and Kagchroo (1964)** in ox mentioned that the ilioinguinal nerve divides into anterior and posterior branches. While **Dyce et al. (2002)** in the ruminant said that the ilioinguinal nerve is the ventral branch of the 2nd lumbar nerve, and passes below the tip of the fourth lumbar transverse process.

Kumar (1998) in goat mentioned that the paravertebral anaesthesia is a regional anaesthesia of the flank; the paravertebral lumbar anaesthesia can be produced by two techniques namely proximal approach (at exit of the spinal nerve from the vertebral canal at the intervertebral foramina) and distal approach (at free end of the lumbar transverse processes). The latter is commonly used where is applied by two methods; vertical and lateral approaches. The vertical approach, the injection site is approximately 3 cm of the midline, while the lateral approach at the ends of the transverse processes of L1, L2 and L3 which are palpated and anaesthesia is injected at each site. While **Garrett (1988)** in goat mentioned that the block of the previous nerves, the anaesthesia injects at the tips of transverse processes of L1, L2, L3 and L4.

4. The genitofemoral nerve:

May (1977) in sheep and **Delahunta and Habel (1986)** in the ox revealed that the genitofemoral nerve pass through the inguinal canal to supply the cremaster muscle. Moreover **Linzell (1959)** in the goat stated that the genitofemoral nerve is a variable and it is formed by ventral branches of the 3rd and 4th lumbar nerves with an occasional small contribution from the second lumbar nerve. **Ghoshal (1975)** in ruminants mentioned that it is formed by a part of the ventral branch of the 3rd lumbar nerve and often receiving a contribution from the ventral branch of second and fourth lumbar spinal nerves

II.B. Diaphragm:

Getty (1975) in ruminants mentioned that the diaphragm is arch shape, broad unpaired muscle which separates between the thoracic and abdominal cavities. The abdominal surface is concave and is covered by transverse fascia and peritoneum. It is fleshy in periphery and tendinous in center. The fleshy part subdivided into a costal, sternal and lumbar which represented by two crura. The sternal part is attached to the abdominal surface of the xiphoid cartilage.

May (1977) in sheep mentioned that the dorsoventral slope of the diaphragm is greatly accentuated and the width is much greater than of the caudal thoracic opening. The midline slopes from the last thoracic vertebra to the level of the ventral end of the 7th or 8th rib.

Al-Safy (2005) in dog mentioned that the diaphragm is a dome shape musculotendinous plate. The center of convexity of the diaphragm was located opposite the middle of the 6th intercostal space while the convexity of the diaphragm was started from the 6th costochondral junction till the upper end of the 12th rib and the body of 12th thoracic vertebra.

Solanki and Sharma (1964); Etemadi (1966); and Selim (1979) in camel found an osseous structure in the central tendon of the diaphragm in close association with the medial part of the foramen vena cava.

Raghavan and Kagchroo (1964) in ox, **Selim (1979)** in camel and **Small Wood (1992)** in horse reported that the muscular part of the diaphragm surrounds the central tendon and its fiber streams into radial direction. It is divided into costal, sternal and lumbar parts.

Getty (1975) in ruminant mentioned that the right crus attaches to the first four lumbar vertebrae by means of the ventral longitudinal ligament. The left crus which is smaller attaches to the ventral longitudinal ligament of the first and second lumbar vertebrae. The right crus divides into two branches which circumscribe the esophageal hiatus to unite ventrally and the spread out the tendinous center.

Ahmad (1999) in buffalo reported that the right and left crura are originated by a large common tendon which attached to the ventral longitudinal ligament at the level of the 2nd – 6th lumbar vertebrae, at the level of 3rd lumbar vertebra, the common tendon subdivided into two tendon, large deep tendon and small superficial one. Moreover the sternal part is an unpaired median part unseparated from the bilateral costal portion its fibers arise on a base of the xiphoid cartilage, the adjacent transverse fascia and the eight costal cartilages, and extend dorsally to the central tendon.

May (1977) in sheep mentioned that the esophageal hiatus lies about 6 cm below the 9th thoracic vertebra. It is situated about hand's breadth ventral to 8th thoracic vertebra and a little to the left of the median plane as mention by **Getty (1975)** in ruminant. **May (1977)** in sheep described that the foramen vena cava slightly lateral from esophageal hiatus and to the right of the median plane.

El-Safy (2005) in dog mentioned that the esophageal hiatus considered more susceptible to hernia than of the aortic hiatus which consider to be more resistant to the hernia due to it was supported by the sublumbar muscles in addition to the tendon of the two crura of the diaphragm.

Ducharme (1990) in bovine mentioned that the hernation of the reticulum through the diaphragm is association with traumatic pericarditis; the hernial ring is usually located at the junction of the musculotendinous portion of the diaphragm ventral to foramen vena cava and lateral to the median plane.

III. Abdominal organs

Rumen:

May (1977) in the sheep mentioned that the rumen is the first part of sheep stomach, occupies most of the left portion of the abdominal cavity and extends over the median plane in the middle and to some extent ventrally. Its long axis is from a point opposite the 8th intercostal space or 9th rib almost to pelvic inlet. Moreover **Dyce et al. (2002)** in the ruminant revealed that the rumen is compressed from side to side and extends from above the middle of the 7th intercostal space or 8th rib to the pelvic inlet and from the left body wall a cross the mid line, especially caudally and ventrally where it reaches to the lower right flank.

Hifny, Ahmed and Ibrahim (1985) in the camel mentioned that the rumen is a large laterally compressed sac which occupies the whole left side of the abdominal cavity extends from the cranial border of the 7th rib till the pelvic inlet, with the average length of 85 cm and 65 cm widths, its capacity ranges from 70 – 100 liters and average weight is about 5 kg.

May (1977) in sheep and **Habel (1975)** in ruminants mentioned that the parietal surface of rumen is related to the diaphragm, left abdominal wall and spleen while the visceral surface is irregular, related to omasum, abomasum, intestine, liver, pancreas, left kidney, aorta and caudal vena cava. While **Hifny et al. (1985)** in the camel reported that the visceral surface is related to the liver, reticulum, omasum, abomasum, pancreas, transverse and descending colon.

Habel (1975) in the sheep and goat mentioned that the ventral sac is relatively larger and extends more to right of median plane than in the ox, its ventral blind sac extends farther caudally 6 to 8 cm than that of the dorsal sac. The parietal surface of the dorsal sac extends caudally to the 2nd lumbar vertebra while till 4th lumbar vertebra as recorded by **Dyce et al. (2002)** in ruminant also added that the ventral blind sac of the goat and sheep is larger than dorsal one and extends caudally than dorsal one, so that the rumen of goat and sheep has an unbalanced appearance. **May (1977)** in the sheep recorded that the cardiac opening opposites of 8th intercostal space about 5 cm below the vertebral column

Both **Garrett (1988)** in goat and **Dyce et al. (2002)** in ruminants revealed that the direct contact of the dorsal ruminal sac with the left paralumbar fossa make auscultation and palpation simple. It also facilitates trocarization for the relief of tympany. The dorsal sac may be palpated per rectum

Cegarra and Lewis (1977) in the goat **Kanwar et al. (1983)** in caprine and **Sharma et al. (1984)** in the ovine said that the rumen occupies the greater part of the abdominal cavity in lateral view with its cranial limit at the level of 8th or 9th and 10th rib respectively and caudal limit at the lumbosacral junction and at the pelvic inlet in the goat and sheep respectively by radiograph with contrast medium. **Zeskov, Petrovic and Dragnovic (1976)** in the sheep and goat recorded that the rumen of sheep and goat is visualized in the left hemiabdomen between the 11th intercostal space and the last lumbar vertebra.

Reticulum:

May (1977) in the sheep observed that the reticulum is piriform in shape, it is the most cranial part of the stomach and lies almost left to median plane against the sternal part of the diaphragm in a transverse plane through the ventral end of the 7th rib or intercostal space, its cranial diaphragmatic surface is within 2.5 cm or less of pericardiac sac in the thoracic cavity. Its cranial extremity is opposite the 5th intercostal space or 6th rib while the caudal border opposite the 8th intercostal space or 9th rib. The lowest point lies about 6 cm above the xiphoid cartilage. The ruminoreticular opening is 6 cm below the vertebral column opposite 9th rib and to the left of median plane. While the reticuloomasal opening is near 8th intercostal space or 9th rib, and it is 3 to 5 cm below the ruminoreticular opening but almost in the median plane.

Delahunta and Habel (1986) in cow revealed that the reticulum is contact with the left abdominal wall at the ventral ends of the 6th and 7th intercostal space and with the ventral wall in the corresponding sternal part. **Habel (1975)** mentioned that the reticulum in the ox is the smallest part of ruminant stomach and located between 6th and 7th or 8th rib. Moreover **Dyce et al. (2002)** in ruminant mentioned that the reticulum extends from 6th to 8th ribs and it reaches from cardia to the most forward of the diaphragm and across the midline, especially ventrally where lies above the xiphoid process of the sternum. **Delahunta and Habel (1986)** in ruminant revealed that the area of auscultation of the reticulum locates at the ventral ends of 6th and 7th intercostal spaces and the pain may be produced by the deep percussion on the left xiphoid region in the traumatic reticulitis. **Hifny et al. (1985)** in the camel mentioned that the reticulum is situated in the right side of the intrathoracic part of the abdominal cavity and extends from the 7th to 10th ribs, it measures about 25 – 40 cm length, while the width reaches about 5 – 8 cm at either ends and 15-20 cm at the middle. Its capacity is about 0.5 liter and average weight about 600 gm. The reticulum is separated from the diaphragm by omasum and does not reach the abdominal floor; the ruminoreticular opening lies dorsal to the medioventral glandular sac at the level of 10th thoracic vertebra, while the reticuloomasal opening is situated at the level of the 7th thoracic vertebra.

Kanwar et al. (1983) in the caprine by radiograph with contrast media observed that the reticulum appears as a void structure situated immediately caudal to diaphragm in the area from 7th to 9th intercostal spaces. **Sharma et al. (1984)** reported that the ovine reticulum extends between 7th and 10th ribs; the reticular fundus is slightly pointed and touched the abdominal floor in the region of the last 2 or 3 costochondral junctions.

Omasum:

May (1977) in sheep mentioned that the omasum is somewhat oval shape and compressed laterally with long axis nearly vertical, lies in relation to 9th to 10th ribs. It has no contact with abdominal wall, being covered by liver on the right, to the left by the rumen and reticulum; whilst the abomasum covers it ventrally. While **Dyce et al. (2002)** in goat mentioned that, it extends from the 8th and 10th ribs. However **Habel (1975)** in ox revealed that the omasum is in contact with right abdominal wall in the ventral of 7th to 9th intercostal space and with abdominal floor in small area between the xiphoid cartilage and right costal cartilage. While **Dyce et al. (2002)** in ox mentioned that, it extends from the 8th and 10th ribs

Sweeney (1988) in the domesticated ruminant and **Green and Backer (1996)** in the African goat described the omasum as a muscular bean shape tube and the omasum of goat is significantly larger than of sheep to body weight.

Hifny et al. (1985) in camel observed that the omasum is situated on the right side of the intrathoracic part of the abdominal cavity from the level of the 7th rib till continues with the abomasum without external demarcation at the level of 10th rib, it reaches about 90 – 110 cm length and 1.5 kg. in weight.

Sharma et al. (1984) in sheep observed the omasum is not visible in survey radiographs. In the barium series, the omasum appears in the lateral radiographs among 10 minutes filling time. It seems to be a bean or kidney shaped structure which is situated between the 9th and 11th ribs in sheep, with a vertical long axis. In the ventrodorsal view the omasum

has rounded shape and presents radiolucent striations, which are best seen in the ventral radiographs.

Abomasum:

May (1977) in sheep observed that the abomasum is elongated tubular structure widest towards the omasal end and narrowing as it approaches the pylorus. It begins centrally in xiphoid region extends backwards gradually inclining to the right along the ventral floor of the abdominal cavity, it runs almost parallel to the right costal arch so that the left border crosses the midline about 10 cm behind the xiphoid cartilage. It then bends up the lateral wall of the abdominal cavity and ends at pylorus at the ventral end of the 10th intercostal space. The greater curvature gives attachment to the superficial part of greater omentum, except at the fundus, where it passes across to the left longitudinal groove of rumen. The lesser curvature is related to the omasum and these parts are united by connective tissue containing some fat. The pyloric part of the lesser curvature gives an attachment to the lesser omentum.

Nickel et al. (1973) in ruminants mentioned that, the abomasum is a bent, pear shaped sac, the fundus and body lies on the abdominal floor caudal to reticulum, the longitudinal axis of this portion crosses the midline somewhat obliquely from the left cranial to the right caudal, overlying the region caudal to the xiphoid cartilage between the ventral ends of the costal arches. The pyloric part is directed dorsolaterally behind the omasum. **Habel (1975)** in ruminant revealed that, the fundus of abomasum lies on the xiphoid region, the corpus lies on the ventral midline with more than half of it on the left, and the pyloric part curves around to the right so that the pylorus is near to the ventral end of right 9th or 10th intercostal space. The abomasum of the sheep and goat lies on the abdominal floor along the right costal cartilages due to the omasum is small and light and is supported on the dorsal surface of the abomasum.

Delahunta and Habel (1986) in the cow mentioned the site for puncture of the abomasum to sample its contents is on the midline, one third of the distance from nick (it marks the junction of xiphoid cartilage with xiphoid process) to the umbilicus.

Cegarra and Lewis (1977) in goat **Kanwar et al. (1981)** and **Sharma et al. (1984)** in ovine observed that the abomasum locates mainly in the cranioventral part of the abdominal cavity with its fundic part between the reticulum and omasum. The pyloric part presents ventrolateral to the omasum. The ventral sac of the rumen is caudal to the abomasum in the lateral view of radiograph with contrast media.

Omenta:

May (1977) in sheep said that the lesser omentum is attached to the ventral part of the parietal surface of the omasum and pyloric part of the abomasum and from the visceral surface of the liver in the region of esophageal notch to the portal fissure. **Habel (1975)**, **Delahunta and Habel (1986)** in ruminants mentioned that the lesser omentum arises from the visceral surface of the liver between esophageal impression and the porta hepatis, and passes to the region of reticular groove, the right face omasum and along the lesser curvature of the abomasum to the first part of the duodenum which return it to the liver.

Nickel et al. (1973) in ruminants revealed that the superficial wall of the greater omentum arises from the greater curvature of the abomasum, the caudal border of the cranial part of the duodenum and from descending duodenum, till the left longitudinal groove of the rumen. The deep layer wall of the greater omentum attaches to the right longitudinal groove of the rumen and passes ventrally in contact with ventral sac of the rumen then turn a dorsally between intestine and the superficial wall of the greater omentum to unite with it on the ventral surface of the descending duodenum, the deep wall attached cranially to the pancreas, dorsal border of the liver and sigmoid loop of the duodenum.

May (1977) in sheep mentioned that the superficial layer is attached to the left longitudinal groove of the rumen to the greater curvature of the abomasum, first part of the duodenum then to colon almost to the level of tuber coxae on the right side, while the deep from the right longitudinal groove of the rumen till mesoduodenum, colon, visceral surface of the liver along the ventral border of the pancreas. The two layers are continuous at the attachment along the caudal groove of the rumen and also join at the iliac flexure of the duodenum at the origin of the colon.

The intestine:

May (1977) in sheep revealed that the duodenum begins at the pylorus of abomasum which is situated opposite the ventral end of the 9th rib space of the right side near the umbilical fissure of the liver. In addition **Dyce et al. (2002)** in ruminant recorded that the duodenum is about 1 m in the length. Moreover **Habel (1975)** in ruminants and **May (1977)** in sheep mentioned that the cranial part of the duodenum passé dorsally to the visceral surface of the liver where it form an S-shaped curve. The descending part run horizontal to the level of the tuber coxae then turns forward again to form the iliac flexure. The ascending part passes forward on the medial side of the descending part and dorsal surface of the terminal part of the descending colon and it form a second-S-shaped curve at the caudal extremity of the right kidney to join the mesenteric part of the small intestine. **Dyce et al. (2002)** in ruminant added that only the descending duodenum is immediately visible on opening the right flank, the first part of the duodenum is attached to liver by lesser omentum and the descending part by mesoduodenum. **Habel (1975)** in ruminant mentioned that the ascending of the duodenum part attached to the descending colon caudally by duodenocolic ligament.

May (1977) in sheep mentioned that the jejunum and ileum pass dorsally across the colon from right to left then ventrally between the colon and the right side of the rumen into a coiled part. The coils pass obliquely across the left side to behind the caudal end of the rumen and thence to the level of the pelvic inlet.

Habel (1975) and Dyce et al. (2002) in ruminant mentioned that the jejunum forms many short coils within the free margin of the mesentery lies within the supraomental recess on the right side of the rumen. Occasionally it is found outside the supraomental recess, caudal and to the left of the ventral sac of the rumen.

Both **Habel (1975)** and **May (1977)** in the sheep mentioned that the cecum has average length 30 cm length and 8 cm diameter. The latter added that the cecum extends about 8 cm behind the right visceral surface of the liver to pelvic inlet. In some cases the caudal end of the cecum may turn left across the median plane to end at the pelvic inlet of

the left side. Moreover, **Dyce et al. (2002)** in ruminant added that the cecum is demarcated from the colon by the entrance of the ileum. Its round, blind tip projects caudally from the supraomental recess and float high when gases filled but sink when its contents are heavier.

Habel (1975) in ruminants mentioned that the proximal loop of the ascending colon begins as the direct continuation of cecum, run forwards 5 to 10 cm to a point opposite the ventral part of the last two ribs, then doubles back between the cecum and descending duodenum, separated from the right paralumbar fossa by the duodenum and the greater omentum, ventral to the caudal flexure of the duodenum. The proximal loop turns medially around the caudodorsal border of the mesentery and runs cranially on the left side of the mesentery. The spiral loop of the ascending colon in sheep and goat is hemispherical shape and consists of three centripetal and three centrifugal turns. **May (1977)** in sheep added that below the fifth or sixth lumbar vertebra the colon turns ventrally to be continued as the spiral part. Moreover, **Badawi; Abd Elrahman, Salem and Mohamed (1999)** in the goat recorded that the spiral loop of the ascending colon of the goat is arranged in coils consisting of centripetal, centrifugal gyri of two and half to three turns each and central flexure. Only the last centrifugal gyrus shows regular constrictions. The distal loop of ascending colon connects the spiral one with the transverse colon. It begins with a constriction at the end of the spiral loop and nearly at the level of a flexure between the proximal and spiral ones.

Badawi et al. (1999) in goat mentioned that the length of the transverse colon about 8 cm and lies in front of the cranial mesenteric artery crossing the median plane from the right side to the left one, relating dorsally to the pancreas and the roof of the abdominal cavity. The descending colon is included in the intestinal disc that found on the right side of the abdominal cavity. It begin on the left side, inclined to the right at the caudal border of the right kidney and then to the median plane shortly after forming the sigmoid colon at the level of the six lumbar vertebra.

Liver:

El-Hagri (1967), Bone (1979) and Dyce et al. (2002) in small ruminant reported that the liver found entirely in the intrathoracic part of the abdominal cavity towards the right side of the median plane with long axis corresponding with curvature of the right part of the diaphragm. The same authors found that the right part of the ventral border of the liver may protrude from under the costal arch opposite to the ninth and tenth intercostal spaces, and its parietal surface is convex and related to the right part of the diaphragm while the visceral surface is irregular and showed reticular and abomasal impression. Moreover, **Awad (2000)** in the goat, recorded that the liver occupying the right hypochondriac subregion, with axis extending cranioventrally from the level of the vertebral end of the 13th rib up to the middle third of the 6th rib and its parietal surface showing costal impression of the last eight ribs however the visceral surface is related to the reticulum, omasum, dorsal ruminal sac, lesser omentum, cranial part of the duodenum and the right kidney.

Both **Anis (1977); El-Gaafary, Mobarak and Anis (1979)** in the buffalo, observed that the liver long axis extends obliquely cranioventrally and medially in conformity with the curvature of the diaphragm from the level of the middle the last rib to the level of the middle third of the fifth intercostal space.

Habel (1975) added that the liver of ruminant is in contact with right abdominal wall from the ventral end of the 7th rib to back to the last rib. The percussion of the normal liver in the ox is limited to the last four intercostal spaces caudoventral to the lung. In some individuals the liver can be palpated in the cranial angle of the paralumbar fossa. In sheep and goat the area of the liver exposed caudoventral to the basal border of the lung is larger. It occupies 7th to 9th intercostal spaces between the lung and the costochondral junctions.

Dyce et al. (2002) in ruminant observed that the area of the percussion of the liver can be detected on over an area centered on the dorsal part of the eleventh rib and eleventh intercostal space. The percussion area is small in relation to the size of the organ and corresponds to the area of directed contact with the body wall. A detectable increase in its extent general signifies an enlargement of the organ. Also he added that, the site of the biopsy specimens. The preferred site for puncture is through the eleventh intercostal spaces in the plane of the lower part of the tuber coxae. The trocar is directed to meet the diaphragm, and thus the liver at the right angles in order to ensure a clean puncture.

Gall bladder:

Habel (1975) and Dyce et al. (2002) in ruminant observed that the gall bladder is pear shaped sac, 10 to 15 cm long in the ox, where it come in contact with abdominal wall at the ventral part of the 9th or 11th ribs. **May (1977)** in sheep mentioned that the gall bladder is long and narrow and extends parallel to the umbilical fissure behind the caudal border of the organ. Its caudal end is beneath the end of the 9th costal cartilage or opposite to the 10th or 11th ribs.

Spleen:

Nickel et al. (1973) and Small Wood (1992) in the small ruminant mentioned that, the position of the spleen is inserted between the dorsal sac of the rumen and the diaphragm and it is firmly attached to both structures by connective tissue. It is found high in the abdominal cavity adjacent to the vertebral column at the region of the tenth to the thirteenth ribs. **Dyce et al. (2002)** in ox mentioned that the site of the biopsy is normally made through the upper end of the eleventh intercostal space and involves the little risk of the injury to the lung.

Pancreas:

May (1977) in sheep mentioned that the pancreas occupies the dorsal region of the abdominal cavity in the vicinity of the crura of the diaphragm and to the right of the median plane. Its left extremity lies between the rumen and the left crus of the diaphragm under the last two thoracic vertebrae and the right extremity is related to the right kidney, the small intestine and the transverse colon.

Habel (1975) in ruminant mentioned that the pancreas is located entirely to the right median plane, it consist of a large right and small left lobe join on the right side of the portal vein, the junction called the body. Opposite the body is a deep notch through which the cranial mesenteric artery and portal vein pass. The body is adherent dorsally to the liver in an area on the right of the porta hepatis, and to the common bile duct and the duodenum. **Dyce et al. (2002)** in ruminant mentioned that the left lobe of pancreas extends across the abdomen, insinuated between the liver, diaphragm and great vessels dorsally and intestinal mass and dorsal ruminal sac ventrally; it thus enters the retroperitoneal area above the

rumen, the right lobe has a more complete peritoneal covering and follows the mesentery of the descending part of the duodenum, ventral to the right kidney and against the flank.

Kidney:

El-Hagri (1967) in small ruminant mentioned that the kidney are smooth rounded bean shaped unipapillary organ. The kidney is about 7.5 cm long, 5 cm in wide and about 3 cm. thick. Right kidney presents under first three lumbar vertebrae. The left kidney as usually pushed entirely to the right of the median plane to lie under the 3rd, 4th and 5th lumbar vertebrae when the rumen full. **May (1977)** in sheep said that, right kidney lies to the right and ventral to the first two or three transverse processes of lumbar vertebrae. While left kidney is usually pushed entirely to the right of the median plane to lie under the 3rd, 4th and 5th lumbar vertebrae when rumen is full, while it returns to left across the median plane when rumen is empty

Ovary:

El-Hagri (1967) in small ruminant reported that the ovaries lie in a position lateral to the coiled uterine horns at about the level of fifth lumbar vertebrae. While both **Shoaib (1999)** and **El-Safy (2001)** in goat mentioned that the ovaries of non pregnant goat are located craniolateral to the middle of the pelvic inlet by about 3 cm from the shaft of ilium while in pregnant goat located craniolateral to pelvic inlet within the abdominal cavity by about 5-6 cm with the coiled gravid uterine horn.

Uterus:

El-Safy (2001) in goat mentioned that the shape of uterine horns are coiled in spiral form and gradually tapering towards the uterine tubes. Moreover **Shoaib (1999)** observed in non pregnant goat the uterine horns reached the abdominal cavity.

El-Safy (2001) in goat mentioned that the topographic position of the non gravid uterine horns are located at the middle of the pelvic inlet while in gravid uterine horns are extended forward till the level of 2nd or 3rd lumbar vertebrae within the abdominal cavity at right side which is related to the right abdominal wall laterally, the descending colon and cecum dorsally and rumen medially. **Dyce et al. (2002)** in cow mentioned that the gravid uterus enter the supraomental recess between the right face of the rumen and the double layer of the greater omentum as it grows and sinks toward the abdominal floor and intestine dorsally.

The urinary bladder:

May (1977) in sheep and **El-Safy (2001)** in the goat revealed that, the urinary bladder is pear shaped. the topographic position of the urinary bladder is a variable according to the fullness state of the bladder, when it empty, it is rested on the pelvic floor, while it extends toward the pelvic brim on the caudal point of the abdominal floor when full of urine, the urinary bladder is related dorsally to uterine body and cervix,

The great arteries within the abdominal cavity.

1. Celiac artery:

Ghoshal (1975) in the small ruminants mentioned that the celiac artery arises from abdominal aorta between the crura of the diaphragm, at the level of the first lumbar vertebra

in the sheep and between the first and second lumbar in the goat. **Karmona et al. (1985)** in sheep observed that the common trunk for celiac and cranial mesenteric is more frequently present in the sheep than in goat.

May (1977) in the sheep and **Ghoshal (1975)** in ox revealed that the hepatic artery give the pancreatic, cystic, right and left branches where the left one is large, this branch give off the right gastric artery which passes along the lesser omentum. The continuation of the hepatic artery is gastroduodenal artery and divided into right gastroepiploic artery which anastomoses with the left one on the greater curvature of the abomasum and pancreaticoduodenal artery which anastomose with the first intestinal branch of the cranial mesenteric artery.

Horowitz and Venzke (1966) in goat and **May (1977)** in sheep revealed that the splenic artery arises frequently with right ruminal artery but in a few cases may be paired vessels. **May (1977)** in sheep and **Dyce et al. (2002)** in the ruminant mentioned that the left ruminal artery may arise from the left gastric and sometimes from the right ruminal artery or from left gastric artery. **May (1977)** in the sheep mentioned that the reticular artery usually arises from the left ruminal artery

May (1977) in sheep mentioned that the left gastric artery is the continuation of the celiac artery which give left gastroepiploic branch also it give the accessory reticular branch

2. The cranial mesenteric artery:

Ghoshal (1975) in the small ruminants mentioned that the cranial mesentery artery arises from the ventral aspect of the abdominal aorta slightly caudal to the origin of the celiac artery when they originate separately or arises by a common trunk with the celiac artery. **Levine et al. (1987)** in the bovine described that the continuation of the cranial mesenteric artery generally parallel the long axis of the jejunum and proximal part of the ileum, providing branches the jejunum from the cranial and ventral surface of the artery. **Ghoshal (1975)** in small ruminants described that the cranial mesenteric gives; pancreatic branches. The caudal pancreaticoduodenal artery arises from the left and the caudal aspect of the parent artery or may originated with the first jejunal artery. The jejunal branches are about 18 to 20 in the sheep. The middle colic artery passes cranially and after that dividing into two or three branches, supplying the ascending colon. **May (1977)** in sheep mentioned that the middle colic artery divides into right and left branches, where supply the transverse and descending colon respectively. **Ghoshal (1975)** in small ruminant mentioned that, the colic branches supply the proximal loop and centripetal gyri and right colic arteries supply the centrifugal gyri and distal loop. They arise from the proximal part of ileocecolic artery. While the colic branches arise from, distal part.

Lymphocenters of the abdominal viscera:

1. Celiac lymphocenter:

Tanudimadja and Ghoshal (1975) in goat revealed that the celiac lymph nodes are inconstant. They may be 3 or 5 in number lying close the origin of the celiac artery, while **El-Gendi (1971)** in buffalo described that they are 1-2 lymph nodes which are scattered along the celiac trunk.

Tanudimadja and Ghoshal (1975) in goat and **May (1977)** in sheep mentioned that the atrial lymph nodes are 2-3 nodes in the sheep and 2-4 in the goat which are located on the atrium of rumen immediately behind the cardia.

Vollmerhaus (1981) in goat mentioned that the right ruminal lymph nodes are situated along the right longitudinal groove and the left ruminal lymph nodes are inconstant and occur in the left longitudinal groove. **Alam Eldin (1984)** in camel mentioned that the left ruminal lymph nodes are not recorded.

Tanudimadja and Ghoshal (1975) in goat mentioned that the cranial ruminal lymph nodes are absent, and the reticular lymph nodes are located in the ruminoreticular groove. **May (1977)** in sheep mentioned that the reticular lymph nodes are situated on the reticulum above and below its junction with the omasum.

Tanudimadja and Ghoshal (1975) in goat described that the omasal lymph nodes are 5-6 ellipsoidal or round lymph nodes lying on the right side of the rumen along the dorsal curvature of the omasum.

Tanudimadja and Ghoshal (1975) in goat mentioned that dorsal abomasal lymph nodes are located along the lesser curvature of the abomasum. **Vollmerhaus (1981)** in the goat, sheep and ox mentioned that the ventral abomasal lymph nodes are inconstant and are situated in the greater omentum of the abomasum.

Tanudimadja and Ghoshal (1975) in the goat mentioned that the reticuloabomasal lymph nodes are 2 ellipsoidal nodes present between the two layers of the omentum along the greater curvature of abomasum and reticulum, and the hepatic lymph nodes are 5-7 in number they lie close to the hilus of the liver between the caudate and papillary process in relation with the portal vein and the hepatic artery they tend to aggregate into a single mass.

2. Cranial mesenteric lymphocenter.

El-Gendi (1971) in buffalo described that the cranial mesenteric lymph nodes are present along the cranial mesenteric artery from its origin till the beginning of its terminal branches while **Saar and Getty (1975)** in ox mentioned that they are situated at the origin of the cranial mesenteric artery, there are few lymph nodes. They are not clearly distinguishable from the celiac, lumbar aortic, and atrial lymph nodes.

Tanudimadja and Ghoshal (1975) in goat mentioned that the jejunal lymph nodes comprise 6 to 40 nodes of various sizes. They are located inside the mesentery. **Lowden and Heath (1993)** in sheep described that the jejunal lymph nodes formed a chain along the length of the mesojejunum, closely adjacent to the cranial mesenteric artery vein and jejunal lymphatic trunk there are 2 types of jejunal lymph nodes, which may be elongated and compact.

Tanudimadja and Ghoshal (1975) in goat mentioned that the cecal lymph nodes comprise two nodes found in the mesentery between the cecum and ileum. While **Lowden**

and **Heath (1993)** in sheep mentioned that the cecal lymph nodes found at ileocecolic junction

Tanudimadja and Ghoshal (1975) in goat mentioned that the colic lymph nodes include a large number of nodes widely distributed along the ventral surface of the initial part of the colon and cranial to the ileums. However **Alam Eldin (1984)** in camel mentioned that, there is no colic lymph nodes found in association with the spiral part of the colon.

IV. Surgical approach of the abdomen:

Kumar (1998) in buffalo and cattle mentioned the sites of the laparotomy included that; mid-flank vertical incision starting from 8 cm below the level of the free ends of lumbar transverse processes, oblique incision in anterior, posterior, middle or lower flank and ventral abdominal incisions which included; the cranial, caudal or, middle midline; cranial, caudal or middle paramedian; cranial, caudal or middle per-rectus and cranial, caudal or middle lateral rectus. Moreover in the mid-flank vertical incision for laparotomy the structures include; skin, cutaneous trunci muscle, subcutaneous fascia and a layer of deep fascia, external abdominal oblique muscle, internal abdominal oblique muscle and transverse abdominal muscle. If the incision is extended more ventrally, the upper portion of rectus abdominal muscle may be incised, and then incised the transverse fascia and parietal peritoneum which form the inner surface of the abdominal wall. In high abdominal oblique incisions all the above structures are cut except the rectus abdominis. While making incision for nephrectomy retractor costal muscle is also incised in between the angle formed by last rib and transverse processes of lumbar vertebra, in addition to above structure.

Othman (1979) in camel an encouraging approach to abdominal surgery in the camel is carried out through flank incisions either at the right or the left side, the midline or paramedian incisions were not preferred due to considerable intra-abdominal pressure excreted by the heavy weight and movement of abdominal viscera which may predispose to prolapse via excessive pressure on the wound especially after operation.

Splenectomy:

Dekock and Gulinan (1926) in cattle, sheep and goats, revealed that, its technique involved partial resection of the last three ribs as this provided an easy access to the spleen and good visibility to the surgical field. **Kumar (1998)** in ruminant denoted that, make incision close to the posterior border of the last rib for an easy access to the apex of the spleen.

Rumenostomy

Both **Berge and westhues (1977)** and **Ducharme (1990)** in bovine mentioned that, the rumenostomy is symptomatic relief of chronic gaseous distension of the rumen, the site of rumenostomy in the left paralumbar fossa at the dorsal aspect of the abdomen a 4 cm skin incision made on the dorsal aspect of the mid portion of the left paralumbar fossa. The incision is sharply extended through the external and internal abdominal oblique muscles, transverse abdominal muscle and peritoneum the rumen is grasped and secure to the subcutaneous tissue with absorbed suture.

Rumotomy

Ducharme (1990) in bovine mentioned that the rumenotomy occurred in left flank by a 22 to 25 cm dorsoventral, skin incision is made 4 cm caudal and parallel to the last rib and 6 to 8 cm ventral to transverse processes of the lumbar vertebrae. The incised the subcutaneous tissue, external and internal oblique abdominal muscles, transverse abdominal muscle and peritoneum are incised in the same plane.

Kumar (1998) in cattle mentioned that the rumenotomy make a 18 to 20 cm long incision is made on the skin starting at a point about 10 cm below the transverse processes of the lumbar vertebrae and in midway of the left flank. The incised the subcutis, and subcutaneous fat, external abdominal oblique muscle, the fiber of which pass somewhat downward and backwards, internal abdominal oblique muscle, fibers of which pass downward and forward Transverse abdominal muscle, deep iliac fascia, subperitoneal fat, parietal layer of peritoneum and the rumen wall.

Abomasotomy

Both **Berge and westhues (1977)** and **Kumar (1998)** in cattle mentioned that, the site of abomasotomy is right parallel to the costal arch starting dorsal cranial superficial epigastric vein and artery. A 12 -15 cm long skin incision is made parallel to the right costal arch. The incision involves the subcutaneous tissue, abdominal tunic, rectus abdominal muscle, transverse abdominal muscle and parietal layer of peritoneum.

Surgical approach of the uterus

Kassem (1983) in goat revealed that. There were many sites to approach to uterus in gravid uterus, hysterectomy and pregnancy toxemia. The sites are the right and left flanks where makes the vertical incision in center of the paralumbar fossa; the paramedian incision which perform as incision 15 cm. in length, lateral and parallel to subcutaneous abdominal vein just cranial to the udder and the midline approach which perform via linea alba and the suitable sits is incision at left flank. **Kumar (1998)** in cow mentioned that the caesarean operation performs by vertical incision on the left lower flank region.

MATERIALS AND METHODS

Twenty Egyptian Baladi goats of the both sex which is divided into eighteen goats from 1 – 3 years old, which included two pregnant goats (four months) and two young goats (three months).

A. The topographic anatomy of the abdomen.

Twelve goats after being bled were injected by ordinary routine method of preservation using 10% formalin, 2% phenol and 1% glycerin for the dissection of the abdomen and study the course and distribution of blood vessels. The arteries and veins were injected with gum milk latex colour red with carmine stain and colour blue with methylen blue (Tomposet and Wakeley 1970) via the common cartoid artery and the femoral vein and superficial epigastric vein respectively.

B. Contrast radiography of the gastrointestinal tract.

Two goats that weighted 25 and 30 kg. were used in this experiment. Barium sulfate suspension (70% W/V) was used as contrast medium at dose of 25 ml/kg body weight. Administration of the contrast medium was made after 48 hr. of fasting of the animals and the water is allowed free, by stomach tube. Lateral and ventrodorsal radiographs taken immediately after administration 10 minutes, 20, 30 minutes and then each hour until 12 hr. Then after 24 and 48 hrs. Employing 25 – 40 kilovolt energy source along with current of 12 – 20 million pers for 0.2 seconds and a distance of 60 – 80 cm.

C. To study the lymph centers of the abdominal viscera.

Two live goats were injected with Evans blue stain 1% solution in the subcuts, muscles and superficial lymph nods, to reach the viscera and other structures, and the animal was allowed to exercise for about 30 minute, then after, the animal was injected with 10% formalin solution after being bled (Alam Edin, 1984).

D. The cross sections of the abdomen

A healthy one adult and one immature goat were sacrificed with chloroform solution. The cadavers were placed in freezer in ventral recumbence. Frozen cadavers were place on the table with band saw and serial transverse sections were cut approximately 3 cm a part. The slices were numbered and cleared by light brushing soaked in water in one goat and complete evacuation to ingesta and let dry in another goat and were photographed immediately with caudal surface toward the camera (El-Safy, 2005).

E. The C.T. images:

The healthy goat used for the C.T. scans after physical examination and fasting for 24 hrs. Then the animal was sedated with 2% xylazine Hcl (0.1mg/kg IV) and was

positioned in sternal recumbancy with the head first during scanning time. It gave slice thickness 1 cm apart intervals on the abdomen at 120 K.V., 200 mps, F3 HF/S and W 200 + 64 was used for all C.T. images. The C.T. images were photographed and compared with the anatomic sections to assist on acute identification of the specific structures (Abu Zaid and Imam, 2000)

F. Surgical approach:

The healthy goat used for surgery after physical examination and fasting for 24 hrs. It was sedated with 2% xylazine Hcl (0.1mg/kg IV) and blocked the nerves of paralumbar fossa by inject of 2 ml of 2% lidocain Hcl at the free end the transverse processes of L1,L2,L3,L4 lumbar vertebrae or line block at sites of operations.

- The nomenclature used in this work is that adapted to **Nomina Anatomica Veterinaria(1992)** as possible

RESULTS

I-The abdomen:

In our study the shape of the abdomen was varied with age, obesity and physiological condition, in young goat the abdomen was compressed laterally and the floor of abdomen was appeared straight, while in the adults goats the abdomen was bulged laterally and the abdominal floor was appeared curved due to the extensions of the size of its stomach. The abdomen was bilaterally symmetrical excepted at advanced pregnancy.

The abdomen was divided into nine regions (**Fig, 1**) by imaginary planes for topographic purposes. The cranial transverse plane passed through the caudal to costochondral junction of last rib. The caudal transverse plane passed through the level of the tuber coxae. The sagittal planes passed at the half way between the midline and tuber coxae. The two transverse planes divided the abdomen into three zones the cranial abdominal region (epigastric region), the middle abdominal region (mesogastric region) and the caudal abdominal region (hypogastric region). The cranial abdominal region was measured about 10-12 cm in length from xiphoid process till the middle of the cranial transverse line, this region was subdivided into xiphoid in middle and two hypochondriac regions laterally. The middle abdominal region (mesogastric region) consisted of the umbilicus and two lateral abdominal regions or right and left flank and was measured about 15 – 18 cm in length. The umbilical region (**Fig, 1/ 3**) characterized by the presence of the scar of the umbilicus (**Fig, 1/ S**) which presented at the level between 1st and 2nd lumbar vertebra. It present behind the xiphoid cartilage by about 13 cm. The lateral abdominal wall characterized by the presence of the paralumbar fossa (**Fig, 2/ 8**) which was triangular depression in the upper part of the flank. It was bounded dorsally by 2nd to 6th lumbar transverse processes which was measured 14 – 18 cm in length, cranially by the last rib which measured about 12-15 cm and caudoventrally by the tension ridge created by the weight of abdominal viscera on the internal abdominal oblique muscle which was measured 13-16 cm (**Fig, 2/ 9**). The caudal abdominal region (hypogastric region) was the smallest region, ending at the pelvic inlet and measured about 6-9 cm in length. It consisted of a median pubic region and right and left inguinal regions which characterized by presence of superficial inguinal ring (**Fig, 4/ 5**).

The spinous and transverse processes of lumbar vertebrae and tuber coxae were well marked (**Fig, 2**). The prominent costal arch, the last sternbra and the xiphoid cartilage were easily palpated

II. Abdominal cavity:

The abdominal cavity was bounded dorsally by six lumbar vertebrae in most cases and in two cases were seven lumbar vertebrae and the associated muscles. The lateral and ventral walls were formed by the abdominal muscles, cranially by a diaphragm and caudally by linea terminalis.

A. Abdominal wall

In our investigation the ventrolateral wall of the abdomen composed of several layers although not all of them cover the entire extent of the ventrolateral abdominal wall.

A.1-The layers of ventrolateral abdominal wall.

1- Skin

In present investigation the skin of the goat was relatively thin, its a thickness was 2 - 2.5 mm. at paralumbar fossa and 2.5 – 3 mm. at the lower part of the flank. The skin was covered by few hairs on the caudal portion of the ventral abdominal wall

2. Superficial abdominal fascia:

It was represented by loose and widely distributed fibers all over the lateral and ventral abdominal wall. It continued with superficial fascia of the shoulder and arm, and caudally, with that of gluteal region. Dorsally it continued to the other side without any bony attachment. Laterally, it invested completely to the cutaneous trunci muscle and extending caudally to the thigh region sharing into the formation of the fold of the flank. Ventrally, it extended from the fascia covering the pectoral region, caudally to the inguinal region through which it invested the preputial muscles and the penis as well as the vaginal process. This layer provided pathway for the cutaneous nerves and enclosed elongated subiliac lymph nodes (Fig. 8/14) which were one large (3 cm x 1 cm) and 3 to 4 small lymph nodes. They lied vertically within the skin fold at the cranial margin of the thigh by 2 cm, above the patella by 6 – 8 cm or at the level ischiatic tuberisoty.

3. Cutaneous trunci muscle (*M. cutaneous trunci*) (Fig. 3/1 and 4/1)

The cutaneous trunci muscle was a sheet of the muscle fibers extending along the lateral thoracic and abdominal walls. The fibers started as a very thin aponeurosis (Fig. 3/4) from the superficial layer of the thoracolumbar fascia. The aponeurosis measured about 5 to 7 cm in length from the middorsal line and ½ mm. thickness. The muscle fibers continued cranially with cutaneous ombrachialis muscle (Fig. 3/ 2) muscle except at upper third where they separated by thin aponeurosis of about 4 to 5cm length. The cranial fibers were directed cranioventrally towards the fascia of the arm and skin flap of elbow and olecranon. The middle fibers were directed cranioventrally toward the umbilical region and attached to lateral border of supramammary or preputials muscles, while the caudal muscle fibers directed caudally toward the superficial gluteal fascia and continued caudoventrally with fold of the flank. Thickness of the cutaneous trunci muscle was 1½ - 2 mm. at paralumbar fossa and 2 - 2½ mm. at flank fold while about 1 ml at the ventral part of muscle.

4. Cranial preputial muscle: (*M. preputialis cranialis*) (Fig. 4/ 2):

In our investigation the cranial preputial muscle was thin flattened bands of 10 cm in length and 2 cm it is maximum breadth. It arose from fascia on the ventral abdominal wall caudal to the xiphoid region by about 1.5 – 2 cm. The bands passed caudally around the umbilicus to unite immediately behind the preputial orifice by 1 cm to blend with fascia of dorsum and lateral surface of the prepuce.

5. Caudal preputial muscle: (*M. preputialis caudalis*) (Fig4/ 3):

It was a long muscular fascicle detached from the cranial end of tuber ischii in common with fibers of semimembranosus muscle by 2-3 narrow tendons, it reinforced by another fascicle originated from the abdominal fascia on a level of the superficial inguinal ring. It terminated at the dorsolateral aspect of the cranial part of the prepuce this muscle was measured about 25cm in length

6. Supramammary muscle (*M. supramammarri*) (Fig3 / 3&9/1):

They were two muscular bands arose from the abdominal tunic caudal the xiphoid cartilage by 6-8 cm. It measured about 10 cm in length then, it terminated by a long common tendon on the cranial aspect of the base of the udder.

7. The flava abdominal tunic (Fig.5/12).

It was yellow elastic sheet covering the distal half of the lateral thoracic and abdominal walls from the 6th rib cranially till the tuber coxae caudally. It was much obvious and could be peeled out at the cranial half of the fleshy portion of the external abdominal oblique muscle and on ventral abdominal wall especially caudal to the umbilicus. The abdominal tunic attached to the lateral distal fourth of 6th rib and extended the middle of the 11th rib. At level of 12th rib it thin out as traced caudally being represented by few fiber covering the caudal part of external abdominal oblique muscle in the flank region. While that covering the ventral abdominal wall was relatively thicker and firmly attached to its aponeurosis a long linea alba. Near the superficial inguinal ring, the fascia diverged into medial and lateral crura covering those of external abdominal oblique aponeurosis and insert with them which gave the medial suspensory ligament of the udder.

8. External abdominal oblique muscle (*M. obliquus externus abdominis*)

The muscle originated from the caudal border and lateral surface of the 6th to 13th rib (Fig.5/1). In addition to the external thoracic fascia interdigitation with the ventral border of serratus ventralis thoracic muscle from 7th to 10th ribs and with the serratus dorsalis caudalis muscle up to the level of the last two ribs. The muscle fibers of the cranial portion ran caudoventrally towards the linea alba while the caudal part came from the last two ribs had horizontal direction, give aponeurotic part at level, 6th lumbar transverse process then terminated in tuber coxae by a short thin aponeurosis. Thickness of muscle at paralumbar fossa was 1.5 – 2 mm, at ribs about 2.5 – 3 mm while the thickness of its aponeurosis was 0.5 – 1 mm.

The muscle terminated by abroad thin glistening aponeurosis divided by superficial inguinal ring into medial and lateral crus. In both epigastric and mesogastric regions the aponeurosis extended for a short distance about 2 cm at level of 6th rib and 4-5 cm at last rib or from linea alba by 3 cm at the 6th rib then gradually increased till reach 9-10 cm at last rib (line of decussation) where the aponeurosis interwoven and over crossed by those of internal abdominal oblique muscle till the linea alba (Fig. 6/1). In hypogastric region the external abdominal oblique aponeurosis continued caudoventrally superficial to that of the internal abdominal oblique up to the linea alba (Fig. 5/2). The inguinal ligament extended from the tuber coxae to cranial half of ventral aspect of the pelvic symphysis instead of the prepubic tendon (Fig. 5/3 and 8).

9. The internal abdominal oblique muscle (*M. obliquus Internus abdominis*):

In the present work, this muscle was represented by a triangular fleshy portion originated from the tuber coxae, upper third of the inguinal ligament and from thoracolumbar fascia by very thin aponeurosis on a level of the last lumbar vertebra. The muscle fibers fanned out cranioventrally lateral to the transverse abdominal muscle and towards the linea alba (Fig.7/5). The fleshy portion thicken gradually as traced caudally, its thickness at the level of 2nd, 4th and 6th lumbar transverse processes respectively was 3 mm, 6 mm and 9 mm. While its length from the base of triangle to apex ranged between 9-11 cm. The muscle was separated from the serratus dorsalis caudalis muscle by triangular gap

in which, both external abdominal oblique muscle and transverse abdominal muscle came in contact (Fig5/6). The most dorsal bundle attached to ventral part of the caudal border of last rib distal to attachment of serratus dorsalis caudalis muscle. The muscle fibers continued cranioventrally by a broad thin, glistening aponeurosis, which terminated at linea alba and prepubic tendon. In epigastric and mesogastric regions, the aponeurosis of the internal abdominal oblique muscle, decussated with aponeurosis of the external abdominal oblique muscle under the lateral border the rectus abdominal muscle by 1 cm and became superficially to aponeurosis of external abdominal oblique muscle (Fig6/1&2), while in hypogastric region, it run under the aponeurosis of the external abdominal oblique muscle. The two aponeurosis made the outer layer of the rectus sheath.

The aponeurosis of internal abdominal oblique muscle before decussated and under costochondral junction of 12th rib by 5 – 6 cm gave a narrow lamina derived from this aponeurosis and run over the inner surface of rectus abdominal muscle and sharing in formation of inner lamina of the rectus sheath.

10. straight abdominal muscle:(M. Rectus abdominis (Fig.7)):

In our work observed that, the rectus abdominal muscle arose by a long thin tendon (Fig.7/I) was 8 cm in length and 2 to 3 cm. width, from the lateral border of the sternum and the costal cartilage of 4th to 8th ribs. It consisted of seven segments of muscle and six transverse tendinous intersection along its length. The first segment (Fig.7/I) of muscle measured about 10 cm in length and 7.5 cm width, while the first tendinous intersection was measured 9 cm length and 0.4 cm width and was very short extending between both borders of rectus abdominal muscle on a level distal to 8th costochondral junction by 2 cm. The 2nd segment (Fig.7/II) measured 9.5 cm length and 4 cm width, while the second tendinous intersection measured 9.5 cm length and 0.5 cm width and presented under the 9th costochondral junction by 3 cm.

The 3rd segment (Fig.7/III) was measured 11 cm length and 3cm width while the 3rd tendinous intersection was measured 11.5 cm length and 0.6 cm width and presented under the 10th costochondral junction by 3.5 to 4 cm. The 4th segment (Fig.7/IV) measured about 12 cm length and 3.5 cm width while the tendinous intersection was measured 12 cm length and 0.7 cm width and presented under the 12th costochondral junction by 6.5 cm, its ventral part was wider than dorsal part.

The 5th segment (Fig.7/V) was measured 12 cm length and 3 cm width, while the 5th tendinous intersection was measured 12 cm length 0.7 width and located under 13th costochondral junction by 13 cm. The 6th segment was measured 11 cm in length and 4 cm width while the last tendinous intersection was measured 11 cm length and 0.5 cm width the last segment was measured about 10 length and 15 cm width (Fig.7/VII)

The medial border of both recti separated from each other by relatively wide space that narrowed as traced caudally. Both recti were attached to the ventral surface of the caudal half of the pelvic symphysis by a narrow triangular prepubic tendon (Fig.7/2) the tendon was measured about 2.5 cm length and 4cm width.

11. Transverse abdominal muscle (M. transversus abdominis)

The transverse abdominal muscle originated by tendinous fibers from the caudal border of the last rib and distal third of 10th , 11th and 12th ribs in addition to the medial

aspect of the costal arch. Its lumbar origin was by a thin aponeurosis from the transverse processes of the first five lumbar vertebrae. This aponeurotic part formed triangular sheet which measured about 8-10 cm at level of the caudal border of the last rib and about $\frac{1}{4}$ to $\frac{1}{2}$ cm till level 5th lumbar transverse process (Fig.8/16 -14/5). The muscle fibers ran distally toward the linea alba. They increased in length as traced caudally which was measured 9 cm at level 5th lumbar transverse process (Fig.8/10). The muscle inserted into the ventrolateral aspect of the xiphoid cartilage and linea alba. Caudal the xiphoid cartilage, the muscle fibers terminated through an aponeurosis increasing gradually in width and decreasing thickness which its length about 3 cm at the level 12th costochondral junction, 7 cm at 13th costochondral junction and 15 cm at level 5th lumbar transverse process. The aponeurotic fibers on its caudal half, passed distally for a short distance of about 1 to 2 cm where it splitted into superficial and deep layers which perpendicular to each other both layers of the transverse aponeurosis ran together medially towards the linea alba.

12. Transverse fascia (Fascia Transversalis):

It lined the inner surface of the transverse abdominal muscle and the most caudal segment of rectus abdominal muscle. It was closely invested by the peritoneum and blended caudally with iliac fascia. Caudally it becomes strong and distinct to compensate the thinness of the caudal portion of the transverse abdominal muscle.

Inguinal canal (canalis inguinalis):

It was represented by a slit-like passage in the caudal part of the abdominal wall. Its craniomedial wall was formed by the caudal portion of the internal abdominal oblique muscle but caudolaterally by the inguinal ligament. The distance between the medial angles of both rings measured about 1 cm. and between the lateral one was about 7 cms. The deep inguinal ring (Fig.12/12) was relatively a long slit measuring about 5 to 6 cm in length, bounded cranially by the caudal margin of the fleshy and aponeurotic portion of internal abdominal oblique muscle, while caudally by the inguinal ligament. The medial angle in turn was rounded, formed by the caudal tendinous part of internal abdominal oblique muscle and lateral border of rectus abdominal muscle, while the lateral one was acute being formed by the union of the caudal border of fleshy portion of internal abdominal oblique muscle and the inguinal ligament. The deep inguinal ring was directed dorsolaterally with a slight cranial inclination. The superficial inguinal ring (Fig.4/5-5/9) was presented between both crura of the external abdominal oblique aponeurosis. It was directed cranially with a slight inclination and measured about 3 to 3.5 cm in length. In the male the cremaster muscle (Fig.12/11) descended through the inguinal canal caudolateral to the spermatic cord in addition to external pudendal vessels and genital nerves in both sexes (Fig.12/7).

Linea alba: (Fig7/12)

It was white fibrous raphe that extended from the xiphoid cartilage till the prepubic tendon. The part of linea alba from the xiphoid cartilage till scar of umbilicus was well defined and measured 11-15 cm in length and 1 – 1.5 cm in width. Caudal the umbilicus it was as thin white line its length was 20 -26 cm and width was 0.5 cm.

A.2. Arterial supply of the abdominal wall

1. Cranial epigastric artery (Fig 8/5 and 9/5.):

The cranial epigastric artery is the caudal continuation of the internal thoracic artery after giving of the musculophrenic branch, at the caudal border of the 7th costal cartilage, it pierced the transverse abdominal muscle then passed caudally in the rectus abdominal muscle till anastomosed with caudal epigastric artery at the umbilical region. It presented away from the mid line by 2-3 cm at cranial part and 4-5 cm at the caudal part

2. Cranial superficial epigastric artery.

A slender vessel supplying mainly the cutaneous trunci muscle and supra mammary in female and cranial preputial muscle in male, and the covering skin. It arose from the lateral aspect of the cranial epigastric artery caudal to the xiphoid cartilage and lateral to mid ventral line by about 3.5 to 4 cm and distal to the costochondral junction of 8th or 9th rib by 4 to 5 cm It pierced the rectus abdominal muscle and the external lamina of the rectus sheath till the cutaneous trunci muscle under the level of 10th costochondral junction by 5 cm. The cranial superficial epigastric artery anastomosed with caudal one at craniolateral to preputial orifice by about 2 cm. (Fig.4/6-8/5' & 9/6)

3. Musculophrenic artery:

The smaller terminal division of the internal thoracic artery at the caudal border of the 7th costal cartilage it ran caudodorsally and laterally on the medial aspect of the costal arch deep to the transverse abdominal muscle

4. The dorsal intercostal arteries

They originated from the thoracic aorta and formed the main blood supply of the costal part of external abdominal oblique muscle from the 7th intercostal to the last one. The last three dorsal intercostal arteries terminal in the transverse abdominal muscle compensating absence of the corresponding ventral ones (Fig.8/1).

5. Dorsal costoabdominal artery: (Fig.8/2)

It originated from the dorsolateral aspect of abdominal aorta between the last thoracic and the first lumbar vertebrae. It proceeded dorsolaterally under the quadratus lumborum and the psoas minor muscles to gain at the caudal border of the last rib caudal to the satellite vein and in front of the cost abdominal nerve where it terminated into the transverse abdominal muscle.

6. Caudal superficial epigastric artery.

In buck it considered as the direct continuation of the external pudendal artery after leaving inguinal canal (Fig.4/7). It passed cranially along side the prepuce accompanied by the satellite vein which away from the mid line by 3-4 cm .it gave branches to prepuce, caudal preputial muscle and scrotum .In female it considered the direct continuation of the cranial mammary artery in front of the cranial aspect of the base of the udder (Fig.9/7)

7. Caudal epigastric artery.

It arose from the pudendo-epigastric trunk; it proceeded cranioventrally on the aponeurosis of the caudal portion of external abdominal oblique muscle, then deep to the lateral portion of rectus abdominal muscle (Fig.9/8 & 12/6)). Where it divided into two branches to the last segments of rectus abdominal muscle.

8. Deep circumflex iliac artery. Fig.12/4)

It arose from the lateral aspect of external iliac artery on level of the last lumbar vertebra. It presented distal to the tuber coxae about 1.5 to 2.5 cm. it divided into a cranial and a caudal branch under cover of the fleshy origin of internal abdominal oblique muscle. The cranial branch ran cranially between the transverse abdominal and internal abdominal oblique muscle, it gave three branches, the dorsal one presented distal to transverse process of 4th lumbar vertebra (Fig.8/3). The caudal branch passed caudolaterally deep to the origin of internal abdominal oblique muscle till terminated into the rectus femoris muscle (Fig.8/4).

A.3. Venous drainage of the abdominal wall

1. The cranial epigastric vein: (Fig10/3&11/3).

It was the second terminal division of internal thoracic vein at the 7th interchondral space. Then passed caudally through the rectus abdominal muscle, then ventral to 8th intercostal space by 4 cm, it gave the cranial superficial epigastric vein.

2. Cranial superficial epigastric vein :(Fig.10/4&11/4)

Considered as direct continuation of the cranial epigastric vein as it pierced the rectus abdominal muscle and external lamina of the rectus sheath to be subcutaneously at the level distal to the costochondral junction 9th rib by about 4 cm and lateral midventral line 3.5-4 cm it proceeded caudally subcutaneously crossing the superficial aspect the cutaneous trunci muscle in epigastric region and continued directly with the caudal superficial epigastric vein in umbilical region. They were far from the midventral line by 2-4 cm during its course; it gave 3 to 4 rami to be distributing in cutaneous trunci and the supramammary muscles in female and the cranial preputial muscle in male.

3. Musculophrenic vein:

The smaller terminal division of the internal thoracic vein arose at the 7th interchondral space lateral to midventral line by 2 to 3 cm. it ran caudodorsally then crossed the medial aspect of the costal arch between costal attachment of transverse abdominal muscle and diaphragm and terminated opposite to the 9th intercostal space by 9th ventral intercostal vein.

4. Dorsal intercostal veins:

From the 7th through the last dorsal intercostal veins drained the external abdominal oblique muscle and cutaneous trunci give cutaneous branches like satellite arteries and the last three terminated in the transverse abdominis muscle.

5. Dorsal costoabdominal vein: (Fig10/1)

It detached from the left vena azygos by a common trunk with last intercostal vein on the level of the last thoracic vertebra. It passed caudolaterally beneath the abdominal aorta deep to psoas minor muscle to gain the caudal border of the last rib in front of its satellite artery.

6. Caudal epigastric vein:

It was detached from the pudendoepigastric trunk. It ran cranioventrally crossing the deep face of internal abdominal oblique muscle to gain on dorsal surface of the rectus

abdominal and enter this muscle and joined with cranial epigastric at level of 6th tendinous intersection.

7. Caudal superficial epigastric vein: (Fig10/5)

It was the direct continuation of the external pudendal vein after emerging from the superficial inguinal ring in male .While in female, it considered the direct continuation of the cranial mammary vein in front of the cranial end of the udder. It proceeded cranially subcutaneously and joined with the cranial superficial epigastric vein. It drained the caudal part of cutaneous trunci, fascia, and skin of ventral abdominal wall, prepuce and mammary gland.

8. Deep circumflex iliac vein:

It was given from the common iliac vein after its origin on a level of the last lumbar vertebra. It presented under tuber coxae by 2-3 cm. It divided into cranial and caudal branches. The cranial one considered the main venous drainage of the caudal portion of the external, internal oblique abdominal muscles, and transverse abdominal muscle (Fig.10/2). The caudal branch passed on medial aspect of tensor fascia lata muscle giving branch to fold of the flank which was considered as the main venous drainage of the cutaneous trunci. It terminated in the rectus femoris muscle.

A.4.The main nerve supply of the lateral abdominal wall:

In present work the paralumbar fossa was innervated by the ventral branches of last thoracic, first and second lumbar nerves in most cases ,but adding ventral branch of third lumbar nerve in two cases

1. The costoabdominal nerve: (Fig. 8/7&10/6)

It was the ventral division of 13th thoracic nerve. It passed caudolaterally, between quadratus lumborum and retractor costae muscle, under the cranial point of 1st lumbar transverse process then passed caudal to last rib 0.5 to 1 cm behind to satellite vessel. Then it divided into lateral and medial rami, the lateral one passed caudoventral to external abdominal oblique muscle then gain to deep face of the cutaneous trunci muscle where it was distributed in its distal portion. The medial ramus descended via the fleshy portion transverse abdominal muscle then passed between latter and rectus abdominal muscle till reached the 6th segment of this muscle.

2. The iliohypogastric nerve (Fig.8/8)

It was the ventral branch of the 1st lumbar nerve in most cases, but in two cases considered as ventral branch of the 1st and 2nd lumbar nerves. It ran caudoventrally and passed under the tip of the 2nd lumbar transverse process. It crossed the deep face of the aponeurotic origin of lumbar part of the transverse abdominal muscle. It pierced the fleshy part of muscle and divided into a lateral and medial branches. The lateral one (Fig.8/8') pierced the external abdominal oblique muscle to gain the deep face of cutaneous trunci muscle where terminated. the medial branch(Fig.8/8'') pierced the transverse abdominal muscle ran distally between it and external oblique muscle for a short distance then continued between the transverse abdominal muscle and internal abdominal oblique muscle to terminated at the 6th tendinous intersection of the rectus abdominal muscle.

3. The ilioinguinal nerve:

It was the ventral branch of 2nd lumbar nerve, but in two cases considered as the ventral branch of the 3rd lumbar nerve. It passed caudoventrally under the middle of transverse process of 3rd lumbar vertebrae then passed under the cranial point of the transverse process 4th lumbar vertebra. The nerve gave the cranial and caudal branches after leaving the spinal canal. The cranial branch (Fig.8/9) gave the medial and lateral rami. The lateral one pierced the transverse abdominal muscle till reach to external abdominal oblique muscle and ramified in the cutaneous trunci muscle. The medial ramus pierced the transverse abdominal muscle then passed between it and the rectus abdominal muscle where it terminated in the last segment of the muscle. The caudal branch (Fig.12/9). Proceeded caudoventrally, gained the deep face of internal abdominal oblique muscle then ramified in the most caudal part of the rectus abdominal muscle

In our work to make blocking to nerves which supplied o the paralumbar fossa we must block the ventral branches of T13 and L1 and L2 by injected anesthetic drug at cranial tip of transverse processes of the L1, L2, L3 and L4.

4. The genitofemoral nerve: (Fig.12/8)

It was the ventral branch of 3rd lumbar nerve, but in two cases considered as ventral branch of the 4th lumbar nerves .it passed under the 6th lumbar transverse process it exchanged fibers with ventral branch of 4th lumbar nerve. Both communicating branch form a nerve trunk and passed distally crossing the deep circumflex iliac vessels to gain the inguinal canal. During its course through, the latter nerve trunk divided into two branches that emitted from the superficial inguinal ring to be distributed in the udder, the abdominal fascia in female and the scrotum and prepuce in the male.

B. Diaphragm:

It was a broad, unpaired muscle which formed a partition between the thoracic and abdominal cavities; it was appeared as a dome shaped musculotendinous plate. The abdominal surface was concave and covered for the most part by fascia which consider as the extension the transverse fascia and peritoneum. The midline slope of diaphragm extended from the ventral extremity of 6th rib till the last thoracic vertebra

The diaphragm of the examined specimens consisted of a small tendinous central part (Fig.13/1), surrounded by radiating muscle fibers of the fleshy part of the diaphragm which dorsally formed two crura of the lumbar part(Fig.13/3&4), laterally by the costal part(Fig.13/2) and ventrally by the sternal part (Fig.13/5).

The lumbar part of the diaphragm (Fig.13/3&4), was formed by right and left crura. The right crus was larger than the left crus. The right and left crura were originated by a large common tendon which attached to the ventral longitudinal ligament at the level of 2nd – 6th lumbar vertebra (Fig.13/6). Then at the level 3rd lumbar it subdivided to give superficial small tendon which was ended at 4th lumbar vertebra and large deep tendon which was ended at 6th lumbar vertebra.

The aortic hiatus (Fig.13/7) was ventral to the last thoracic vertebra and between the two crura of the diaphragm. The esophageal hiatus (Fig.13/8) passed via right crura at the level of ventral to 9th or 10th thoracic vertebra by 6 cm .The foramen venae cavae

(Fig.13/9) was presented in the median plane and below the esophageal hiatus by 1 – 1.5 cm.

the costal part of the diaphragm (Fig.13/2) consisted of muscle fibers radiating from the costal wall to tendinous center by indistinct serrations from the 9th rib, from its costochondral junction by 2 to 2.5 cm area of attachment, by about 4-4.5 cm area of attachment to 10th rib proximal to its the costochondral junction, by 6-7 cm area of attachment proximal to the 11th costochondral junction, by about 8-9 cm from 12th costochondral junction and to the last rib about 2 cm ventral to its vertebral end.

The sternal part of the diaphragm (Fig.13/5&14/3) was separated from the costal part by two thin fiber bands. Its fibers were raised on the base xiphoid cartilage and attached to 8th costal cartilage on each side, so that the sternal part susceptible to hernia, because it was separated by thin fibrous bands which gave it more weakness

III-Abdominal organs

Rumen:

The rumen was the first part of the goat stomach, occupied the most of the left portion of the abdominal cavity. The ventral ruminal sac extended right to median plane especially at the middle (Fig.22/3). It was extended from point opposite to the 8th rib, or 9th rib to the level of the tuber coxae. The dorsal curvature of the rumen was related to the left crus of the diaphragm and the sublumbar muscle to which the rumen was firmly attached by peritoneum and connective tissue to the level of the 2nd lumbar vertebra. The ventral curvature lied on the floor of the abdomen mainly left of the median plane, especially in the xiphoid region. The parietal surface was related to the diaphragm, the left abdominal wall and spleen. The visceral surface (Fig.18/12) was irregular and was related to omasum, abomasum, liver, pancreas, left kidney, intestine which lied chiefly in contact with right surface of the rumen, aorta and caudal vena cava.

The dorsal ruminal sac (Fig.16/7 &37/12) situated to the left of the median plane, at the level of 8th intercostal space and extended about 6-8 cm. further forward than the ventral ruminal sac and reached caudally till the level of 5th the lumbar vertebra, it came in contact with the left paralumbar fossa so that the site of auscultation and palpation of the rumen presented at the level of 3rd lumbar transverse process. The best site for trocarization for the relief of the tympany presented under the 3rd lumbar transverse process by 3-5 cm, while in late pregnant female and immature goat, it preferred at under the 2nd lumbar transverse process due to the rumen reach caudally to 3rd lumbar vertebra in pregnant goat and at the junction between 4th and 5th lumbar vertebrae in immature goat. The ventral ruminal sac (Fig.16/6, 8&10) extended from 10th intercostal space till the level of the tuber coxae, it was larger than dorsal one and back for a distance about 3-4 cm. than the dorsal ruminal sac. It was enclosed in the greater omentum. The cardiac opening presented at the level of 8th intercostal space or 9th rib at 5-6 cm below the vertebral column.

In one specimen was fasted for 48 hrs. The rumen (Fig.17/4&5) extended from 8th intercostal space till the level of 5th lumbar vertebra and the intestine was appeared in the left flank. In late pregnant female the gravid uterus pushed the rumen till a level of the 3rd lumbar vertebra. In 3 month old goat (Fig.43/21) the rumen reached to the junction between 4th and 5th lumbar vertebrae and its ventral sac extended more to right side.

The rumen appeared completely in lateral (Fig.27/3&4) and ventrodorsal abdominal radiographs (Fig.28/6&7) with contrast media, where barium sulfate was administered and until about 1 hour in association with reticulum, omasum and abomasum. It was extended from 8th rib cranially to the junction between the 6th lumbar vertebra and sacrum caudally and from vertebral column dorsally to abdominal floor ventrally.

Reticulum:

The reticulum was piriform in the shape, lied almost entirely to the left of the median plane. It extended from the 6th rib or 6th intercostal space to 8th rib or 8th intercostal space. It had 15 cm length and width 6-8 cm in middle and 1-2 cm at extremities and extended ventrally till the abdominal floor (Fig.16/3&37/9) and from 5th to 7th intercostal space in late pregnant female. The parietal surface was convex, and related to the diaphragm and the liver. The visceral surface was related to the rumen, omasum and abomasum. The lesser curvature faced the right and dorsally and connected with omasum by a short neck, while the greater curvature directed the left and ventrally which presented opposite the 6th intercostal space. The ruminoreticular opening was presented below vertebral column by 6-7 cm. and opposite the 9th rib (between upper and middle third of 9th rib) and left to median plane. The reticulomasal opening presented under the ruminoreticular opening by 3-4 cm almost in median plane (Fig.28/3). In 3 months old goat, the reticulum extended from 6th to 8th ribs and was presented above sternum by 6 cm. so that gave space to abomasum to began from 6th intercostal space (Fig.43/9&10). The area of auscultation of the reticulum located at the ventral end of 6th and 7th intercostal space in adult goat. The site of the percussion of reticulum was detected at the left part of xiphoid region

In the lateral abdominal radiographs with contrast media, the reticulum appeared as piriform and was located just behind diaphragm it extended from 6th or 7th to 8th intercostal space or 9th rib, ventrally it touched the abdominal floor in the xiphoid region. It was demonstrated immediately just after barium administration and until the 48 hrs (Fig.26/1 &31/1). In the ventrodorsal view the reticulum was located in left side of the abdominal cavity (Fig.28/1).

Omasum:

It was bean shape, lied in the intrathoracic part of abdominal cavity right to the median plane between the liver on the right and rumen and reticulum on the left and abomasum ventrally (Fig.33/d & 37/13), so that it hadn't contact with abdominal wall. It extended from a level of 7th intercostal space or 8th rib till the 9th intercostal space or 10th rib, while at 7th to 9th ribs at late pregnant goat and in immature goat, exactly at the middle third of dorsoventral diameter. It was measured 10 cm length and 5 cm width. The parietal surface faced to right and related chiefly to liver, while the visceral surface faced in the opposite direction and was in contact with ventral ruminal sac, reticulum and the abomasum. The greater curvature faced caudally and to right while the lesser one was relatively short faced cranially and to left. The omasal neck was a very short and narrow part connected the omasum and reticulum. It presented at the level of the distal half of middle third of 8th rib and about 10-12 cm, under the vertebral column. The omasoabomasal opening presented under the reticulomasal opening by 2 cm. at the median plane.

In lateral radiograph with contrast media, the omasum was identified after 10 minutes of a barium administration as bean shaped structure. It extended from 8th to 10th rib (Fig.31/2). In ventrodorsal radiograph, the omasum appeared as circular shaped organ located mostly in right side of abdominal cavity which extended from 8th to 12th interchondral spaces (Fig.28/2). It was best seen in the ventrodorsal radiograph it was clearer than the lateral one.

Abomasum:

It was elongated tubular structure widest towards the omasal end and narrowing as it approached to the pylorus. It extended from the 8th intercostal space till 12th intercostal space or 13th rib, while in late pregnant goat, it extended from 8th to 10th intercostal spaces, while in immature goat it extended from 6th to 11th intercostal space (Fig.43/10). The length of abomasum was about 80 cm and its width ranged from 10 cm, 4 cm, and 2 cm in fundus, body and pyloric parts respectively. The fundus of abomasum lied centrally in the xiphoid region with relation to the liver and the reticulum (Fig.16/11). The body of abomasum extended on the abdominal floor then inclining to right and extend a little ventral to right costal arch and almost parallel with it (Fig.22/4). The pyloric part turned to the right caudal to omasum, and bend up to lateral wall of the abdominal cavity till ended at the pylorus at the ventral fourth of the 10th intercostal space or the 11th rib (Fig.20/6). The omasum was small in goat, so that allowed to the abomasum run parallel to the right costal arch. The parietal surface was related the right abdominal wall below the costal arch, while the visceral surface was related to the rumen and omasum. The greater curvature was ventrally directed and gave attachment to superficial part of the greater omentum except at fundus. The lesser curvature was directed dorsally and gives attachment to the lesser omentum. The site of puncture abomasum to sample its content was behind the xiphoid cartilage by 5-6 cm and to right 2 cm from the ventral midline. (Fig.22/7)

In X-ray with contrast media. The abomasum began to appear after 20 minutes. It was noticed in the ventral part of cranial abdominal region being insinuated between the reticulum cranially and ventral ruminal sac caudally. Only the fundic region was clear in lateral radiograph due to superimposition of the rumen (Fig.26/2). In ventrodorsal radiographs, the abomasum located completely in the right side of the abdominal cavity, it extended from the 8th intercostal space to 12th intercostal spaces. The pylorus was noticed to be directed cranial to reached 11th intercostal space, after 1-1.5 hr., it was filled with contrast media and still presented until 48 hours.

Omenta:

The greater omentum was consisted of two layers, superficial and deep layers. The superficial one arose from the left longitudinal groove of the rumen (Fig.15/2), while the deep layer arose (Fig.20/12) from the right longitudinal groove of the rumen and the both layers united on the ventral surface of the descending duodenum, dorsal to the deep layer of greater omentum presented the supraomental recess which contained the most of the intestine. The opening of the recess lied caudally at the level 5th transverse lumbar process. (Fig.19/6),

When we made the laparotomy in the left flank, we observed the dorsal ruminal sac, and the ventral sac was covered by the superficial layer of greater omentum (Fig.15/1&2),

when we made the laparotomy in the right flank, we observed greater omentum, the descending duodenum and mesoduodenum. (Fig.19/1, 2&3)

The lesser omentum (Fig.23/12) was represented by an extensive peritoneal fold attaching to the visceral surface of the liver to the abomasum and cranial part of the duodenum. It distinguished into two visible ligaments hepatogastric and hepatoduodenal. The hepatogastric ligament arose dorsally at the esophageal impression where it continued with the falciform, left triangular and coronary ligaments and from the cranial end of the porta hepatis. While it inserted at a line extending from fundic part of the abomasum, and lesser curvature of the reticulum as well as parietal surface of omasum. The hepatoduodenal ligament attached from the porta hepatis, while the duodenal attachments occur at the cranial part of the duodenum. This ligament was contained the common bile duct, hepatic artery, lymph and nerves.

Intestine:

The small intestine consisted of three parts, the duodenum, jejunum and ileum. In present study the duodenum extended from the pylorus at the ventral fourth of 10th intercostal space to duodenojejunal flexure at the level of the ventral end of 12th or 13th rib. The cranial part of the duodenum passed dorsally to the visceral surface of the liver where it formed S-shape flexure (Fig.21/7) at the between middle and distal thirds of 11th intercostal space or 12th rib, where the common bile duct was opened in the caudal part of the S-shape duodenal flexure. it was attached a long its cranial surface to lesser omentum and a long its caudal surface to the superficial wall of the greater omentum.

The descending duodenum (Fig.20/8 &23/11) run caudal till the level 5th lumbar transverse process while in two specimens at the level of the 4th lumbar transverse process under it by 5 cm, when made laparotomy from the right flank the cranial, descending and caudal flexure of the duodenum were only parts of the intestine were exposed. The descending duodenum and caudal flexure were attached to the mesoduodenum (Fig. 20/10), the descending part was attached ventrally to greater omentum.

The ascending duodenum (Fig.18/1) passed cranially medioventral to descending colon where attached with them by duodenocolic ligament (Fig.18/9) and dorsally to the distal loop of the ascending colon then form duodenojejunal flexure (Fig.18/2) at the level of 1st or 2nd lumbar vertebra then gave the jejunum.

The jejunum was the longest part of small intestine (Fig.18/4 &21/10). It formed a numerous close coils arranged in a festoon around the free border of mesentery. It lied in the supraomental recess on the right side of the abdominal cavity, mainly in distal third of mesogastric and hypogastric regions. Sometimes it presented out side the supraomental recess and it was appeared in the left side behind the caudoventral blind sac of the rumen. In animal was fasted for 48 hrs. the most of jejunum and large intestine presented out side supraomental recess and shifted to left behind the rumen, from 5th lumbar vertebra till the pelvic inlet (Fig.17/7,8&9). In one specimen, the jejunum made a circular shape instead of the festoon shape (Fig.18/3).

The ileum was a short part of small intestine (Fig.21/11). It entered the cecum at the junction between it and ascending colon, at the level of hip joint and under the level of transverse process of 3rd or 4th lumbar vertebra by 14-16 cm.

In X-ray with contrast media, the small intestine began to have contrast material after one to three hours after barium administration. In the lateral radiographs (Fig.29/6). It was not appeared in the area covered by the rumen but only detected just behind it as convoluted radiolucent bands and could not be differentiate between each part of intestine excepted the ileum(Fig.29/7)., due to the relation to cecum. In the ventrodorsal view (Fig.30 /3) the small intestine was located in the right side of the abdominal cavity between the rumen and the right abdominal wall.

The large intestine consisted of the cecum, colon and rectum; generally the large intestine occupied the right middle and upper thirds of abdominal cavity. Cecum was cylindrical barrel shaped organ, presented in the supraomental recess except its apex (Fig.20/13). It located against the right flank separated from it by the greater omentum, in the dorsal caudal two thirds of the abdominal cavity and extended from the 3rd or 4th lumbar vertebra till the pelvic inlet (Fig.21/12). Its end projected freely from opening of the supraomental recess. In some cases the apex of the cecum might be present the left side of pelvic inlet due to its bent (Fig15/3&.17 /8). In X-ray the contrast material it began to enter the cecum after 3.5 to 4 hrs after administration of barium, become clear after 6 hrs. It still presented until 48 hrs. In lateral radiograph, the cecum appeared as cylindrical or U-shape structure present under 4th lumbar vertebrae till the pelvic inlet (Fig.31 /7). In the ventrodorsal view, it was located entirely in the right side of the abdominal cavity. The shape and position of the cecum influenced by its content, it floated high when filled with gases and sink when it filled by ingesta.

The colon was divided into ascending, transverse and descending colon. The ascending colon consisted of three loops .The proximal loop of ascending colon began at the level of the hip joint and under the 3rd or 4th lumbar vertebra by average length 14 cm (Fig.21/13). it consisted of three parts, ventral, middle and dorsal which formed S- shape and presented under the level the from 2nd to 6th lumbar vertebrae (Fig.18 /5). In X-ray with contrast media was appeared in the proximal part of the ascending colon at 4hrs after barium administration (Fig.29/9), but complete filling after 6, 5 hrs. It appeared in lateral radiograph as U-shape.

The spiral loop of the ascending colon was hemispherical and arranged in coils consisting of the centripetal and centrifugal gyri of two and half to three turns of each and central flexure(Fig. 18/6,7&8) respectively . The spiral loop located under the level of 2nd to 5th or 6th lumbar vertebrae at right side at the middle third of the abdomen. In our study the spiral loop in one specimen had special arrangement (Fig.24). This made at first one turn of centripetal, two centrifugal gyri then one centripetal turn and finally one centrifugal turn. In total it had 2 centripetal gyri and three centrifugal gyri and three flexures. In X-ray, the contrast medium observed in the spiral colon among 8hrs. The spiral loop was not clearly demonstrated, since the coils were obscured by the rumen and cecum and the overlapping of its loop over each other. The distal loop of the ascending colon was the continuation of the last centrifugal coil, consisted of the dorsal and ventral parts the dorsal one directed caudally, while the ventral one directed cranially till the transverse colon. It located in upper third of abdomen under the level of 1st to 4th lumbar vertebrae (Fig.21/4). The transverse colon lied in front the cranial mesenteric artery, crossing the median plane from right side to the left one under the 1st lumbar vertebra.

The descending colon (Fig.20&21/15) run caudally dorsal to the ascending duodenum, it began under the 1st lumbar vertebra, while in one case began under the 13th thoracic vertebra. It began on the left side, inclined to right at the caudal border of the right kidney then to median plane shortly after from the sigmoid colon (Fig.21/16) at the level of the six lumbar vertebra. In lateral radiographs the descending colon was identified by its contents of the fecal pellet that covered by barium after 9hrs. It located at the roof of the abdomen and run caudally to give the sigmoid colon under the 6th lumbar vertebra (Fig.30/5)

Liver:

In our examined adult animals, the liver of goat was situated in the intra thoracic part of the abdominal cavity occupying the right hypochondriac region. Its long axis extended cranioventrally from the level of vertebral end of 13th rib up to distal part of 6th intercostal space (Fig.23/1,2,3 &4) while to level between middle and distal third of 6th intercostal space in immature goat (Fig.43/12). The visceral surface was related to reticulum, atrium of rumen, omasum, lesser omentum and cranial part of the duodenum and the right kidney.

The sites of percussion of the liver were detected at distal third 7th to 9th intercostal spaces and at area centered on the dorsal part of 11th intercostal space. So that the dullness sound of the liver appeared after last rib that indicated the enlargement of the liver. The site of biopsy of the liver was located at the upper fourth of 11th or 12th intercostal spaces and in the plane lower to tuber coxae the trocar was directed to meet the diaphragm and liver at the right angle at 11th intercostal space or by acute angle at the last intercostal space that sites avoid the entrance in the right pleural sac and large vessels in liver (Fig.23/10 &10').

Gall bladder:

The gall bladder was piriform shape and had three parts; funds, body and neck. It projected 0.5 to 3.5 cm lower than the ventral hepatic border. It came in contact with lateral abdominal wall at ventral end of the right 10th intercostal space (Fig.23/5&43/23). So that the injection in gall bladder especially in direct method of cholecystograph and sampling from it. The canula introduced in the gall bladder from right side at 10th intercostal space at mid way between the vertebral column and sternum (or at ventral part of 10th intercostal space).

Spleen:

It was oval in shape, situated between the dorsal ruminal sac and diaphragm and adjacent to the vertebral column at the caudal border of upper fourth of left 10th rib till the cranial end of the transverse process of the 1st lumbar vertebra (Fig.16/2&37/11). In the lateral spleenography appeared as the triangular shape with uniform density just ventral to vertebral column extending cranioventrally from 13th rib to 10th rib cranially (Fig.27/7). The site of biopsy of the spleen was at the upper fourth of left 12th intercostal space, with right angle to spleen (Fig14/7).

Pancreas:

The pancreas was located in the dorsal abdominal cavity, right to median plane under the 11th thoracic vertebra till the first lumbar vertebra, under the vertebral column by 4 to 6 cm (Fig.37/18). It consisted of a large right lobe, body and left small lobe. The right lobe was large covered by peritoneum lied under the caudate lobe of the liver and ventral surface of the right kidney and presented dorsomedial to the end of distal loop of the ascending colon and transverse colon (Fig.21/4). The body was small size and had deep pancreatic notch for portal vein. The left lobe was retroperitoneal lied between dorsal ruminal sac and the left crus of the diaphragm and celiac trunk (Fig.33/A). In the goat the major pancreatic duct only was present and opened together with common bile duct in duodenum.

Kidney:

The kidney was smooth and bean shaped unipapillary organ. The right kidney. In one case located under the last thoracic vertebra till the 2nd lumbar vertebra (Fig.23/6), while in most specimens extended from 12th intercostal space to the transverse process of 1st lumbar or 2nd lumbar vertebra (Fig.20/14). The right kidney was supplied with the right renal artery which arose from abdominal aorta at the level 2nd lumbar vertebra the directed cranio-laterally and ventrally then divided at the hilus into 3 small branches.

The left kidney was presented just caudal to the right kidney in most specimens which was pushed entirely to the right of the median plane and lied under 2nd, 3rd and 4th lumbar vertebrae (Fig.18/10), but in one case was located under 3rd, 4th and 5th lumbar vertebrae. While In fasten goat and immature goat the left kidney presented left to median plane and lied under 3rd, 4th and 5th lumbar vertebrae (Fig.17/13 & 43/33).

The left kidney was supplied by the left renal artery which arose from abdominal aorta at the level of 3rd lumbar vertebra and directed caudoventrally and divided into 3 large branches before hilus by 2 cm. it measured about 5-5.5 cm.

Ovary:

In all studied female goats, the shape of the ovary was irregular shape, the ovaries of non pregnant animals were located cranio-lateral to middle of pelvic inlet by 2 cm from the shaft of ilium and lateral to coiled uterine horn, while the ovaries of pregnant goat was located cranio-lateral to pelvic inlet within the abdominal cavity with the coiled gravid uterine horn by about 5-6 cm from pelvic inlet (Fig.25/1)

Uterine tube:

It extending from the tubal extremity of the ovary to the corresponding uterine horn, where it opened by a narrow small opening. The uterine tube in all investigated non pregnant animals located at cranio-lateral to the pelvic inlet by about 3 cm from shaft of the ilium while in pregnant goat presented in the abdominal cavity cranial to pelvic inlet by 6-8 cm (Fig.25/2).

Uterus:

The non gravid uterine horns (Fig.20/17) were located at the middle of the pelvic inlet in part and another part in abdominal cavity, its relation was the rectum dorsally and pelvic floor or urinary bladder ventrally when distended with urine. While the gravid

uterine horn was extend till 2nd or 3rd lumbar vertebra in right side of the abdominal cavity (Fig.25/3) which pushed the greater omentum and content of the supraomental recess to upper third of the abdominal cavity , The uterine body was located at the pelvic cavity followed the uterine horns in non pregnant animals related dorsally by rectum and ventrally by the urinary bladder, while in pregnant one, it was located within the abdominal cavity followed the uterine horn with its caudal part at pelvic inlet (Fig.23/17) .The uterine cervix was completely located within the pelvic cavity in non pregnant animals while in the pregnant animal it was rested on the pelvic brim.

Urinary bladder:

In most investigated animals, it was pear shaped. The position of the bladder was different greatly according to the state of the fullness, as that when it was empty it wrinkled in appearance and located on the pelvic floor (Fig. 12/16) when full of urine it was extended to reach the pelvic brim or abdominal floor (Fig21/18.).

The great vessels within the abdominal cavity:

1. Celiac artery:

The celiac artery arose from the ventral aspect of the abdominal aorta, under the 1st lumbar vertebra. It arose separated from cranial mesentery artery by 0.5 to 1 cm (Fig.32/2). The celiac trunk gave off three main branches; hepatic, left gastric and splenic arteries and supplied the caudal third of esophagus, stomach, liver, spleen, pancreas and cranial third of duodenum.

The hepatic artery gave the following branches (Fig.32/5), the right hepatic; left hepatic branches (Fig.32/10&12) which supplied the liver, the right hepatic branch gave the cystic artery which supplied the gall bladder (Fig.33/13). The right gastric artery arose from left hepatic artery (Fig.32/13) passed on the lesser curvature of abomasum and anastomosed with the left gastric artery. The gastroduodenal artery was the terminal branch of hepatic artery (Fig.32/14) which divided into cranial pancreaticoduodenal artery and right gastroepiploic artery. The cranial pancreaticoduodenal artery anastomosed with the caudal pancreaticoduodenal artery (Fig.32/15), while the right gastroepiploic artery passed on the greater curvature of the abomasum and anastomosed with the left one (Fig.32/16&19).

The left gastric artery (Fig.32/4) was longer branch passed in lesser omentum along the lesser curvature of abomasum and anastomased with right one .The left gastric artery gave the reticular (Fig.32/17), left gastroepiploic (Fig.32/19), omasal and accessory reticular branches(Fig.30/18).

The splenic artery (Fig.32/3&33/6). gave three terminal branches ; splenic, right ruminal and left ruminal (Fig.32/6,8&9) respectively which passed to splenic hilus ,right and left longitudinal grooves of the rumen respectively .

2. The cranial mesenteric artery:

It arose from aorta just caudal to the celiac artery (Fig.33/3). It supplied the most parts of small and large intestine. It gave the following branches; pancreatic branch, caudal pancreaticoduodenal artery which supplied the ascending duodenum and anastomosed with cranial one; the middle colic which supplied transverse colon and

descending colon (Fig.34/2); the ileocolic artery (Fig.34/3) which gave off the following branches; the right colic; colic; ileal mesenteric and cecal arteries. The right colic arteries (Fig.34/7) supplied the distal loop of the colon and centrifugal gyri. The colic branches supplied the centripetal and proximal loop of the ascending colon and in one case arose from the proximal part of ileocolic artery (Fig.34/6). The ileocolic artery gave small branches to the proximal part of ascending colon (Fig.34/10). The ileocolic artery at the level of ileocecolic junction gave the ileal mesenteric branch (Fig.34/9) which anastomosed with ileal branch and cecal artery passed on the ileocecal fold and gave branches to cecum and ileum and terminate in the antimesenteric ileal branch. The jejunal (Fig.34/5) arteries originated from the convex surface of the whole length of the cranial mesenteric artery ranged between 16 – 20 branches. The ileal artery (Fig.34/11) arose from the terminal branch of cranial mesenteric artery which anastomose with mesenteric ileal artery.

Lymphocenter of the abdominal viscera;

1. The celiac lymphocenter.

Atrial lymph nodes; they were four in number which measure 1 -1.5 cm in diameter, they lied on the visceral surface of ruminal atrium behind the cardia (Fig.35/1)

Right ruminal lymph node; They were three which measure 1.5 – 2 cm in diameter and another three were small less than 0.5 cm in diameter. They found along the right longitudinal ruminal groove (Fig.35/2).

Omasal lymph nodes; they were three presented on the dorsal curvature of omasum which measure 2 cm in diameter (Fig.35/3&43/18).

Dorsal abomasal lymph nodes: They were five lymph nodes about 1 – 2 cm in diameter and present at the lesser curvature of the abomasum (Fig.35/4&43/17)

Hepatic lymph node; they were five which measure 0.5- 1 cm. at porta hepatis

Pancreaticoduodenal lymph nodes; they were three lymph nodes presented along course of the pancreaticoduodenal artery (Fig.36/10)

2. The cranial mesenteric lymph center:

Jejunal lymph nodes: The jejunal lymph nodes located inside the mesentery, closely adjacent to the continuation of cranial mesenteric artery. They were two types elongated and compact jejunal lymph nodes. The elongated jejunal nodes (Fig.36/1) were varied in length from 4 cm to 15 cm and 2 to 3 in numbers. The compact jejunal nodes were rounded or bean shaped. They were 7 – 10 in number and size from 1 to 2 cm. (Fig.36/2).

The cecal lymph nodes: they were two lymph node which presented at the wall of ileocecolic junction (Fig.36/3).

Colic lymph nodes ; They were scattered on the spiral loop of ascending colon , they were 9 – 12 lymph nodes with varied sized from 0.5 to 2 cm. (Fig.36/4).

IV. The cross sectional anatomy of the abdomen:

The results of our study denoted the seven cross sections of the abdomen in adults goat and nine cross sections in three months goat. Attempts were made to slice the cadaver exactly perpendicular to the long axis, not all structures were labeled in every slice. In the cranial abdomen region of the adult goat. The 1st slice contained the left and right caudal

lobes of the lung (Fig.37/2&3) and left vena azygos and aorta (Fig. 37/4&5) in the dorsal part. The reticulum (Fig. 37/9) appeared on the left side and contact the ventral abdominal floor, while the liver presented in the right side (Fig.37/8) also the caudal vena cava located dorsomedial to the liver (Fig.37/10). The 2nd slice showed the appearance of the dorsal ruminal sac (Fig.37/12) which located on the dorsolateral part of the left side, while the abomasum located in the ventrolateral part of the left side (Fig.37/15). The omasum located in the central of the middle between the dorsal ruminal sac and abomasum on the left and the liver on the right (Fig.37/13). The spleen observed on the dorsal ruminal sac (Fig.37/11).

The 3rd slice explained the presence of the pancreas (Fig.37/18) at the dorsal part between the dorsal ruminal sac and the liver also appearance of the ventral ruminal sac in the ventrolateral part of the left side (Fig.37/17) and the abomasum shifted to center and right side. In immature goat, the reticulum presented in the left and extended to right and come in contact with right abdominal wall (Fig.43/9), the omasum was relatively small than in adult (Fig.43/15) and abomasum located under the reticulum which extend from the 6th intercostal space till reach till 11th intercostal space (Fig.43/10).

In the middle abdomen region of the adult goat. In 1st slice explained the dorsal and ventral ruminal sacs occupied the left part, the ventral one extended over than the midline (Fig.38/2&3). Duodenum (Fig.38/6) located in the right dorsolateral part under the right kidney and contacted with right abdominal wall. The jejunum (Fig.38/13) presented in the ventral part of right side. The distal loop of the ascending colon (Fig.38/10) observed right to the dorsal ruminal sac. The descending colon presented between the right kidney and the dorsal ruminal sac (Fig.38/11). The right kidney located dorsolateral of the right side (Fig.38/12). The 2nd slice of showed the left kidney presented at the right to the median plane (Fig.38/16). The ascending colon located in the right dorsal and middle thirds of abdominal cavity which represented by proximal loop, spiral loop and distal loop of ascending colon (Fig.38/10, 18&19). In immature goat, the ventral ruminal sac extend to right and might contact to right abdominal wall (Fig.43/21). The left kidney (Fig.43/33) located in left dorsal midline. The dorsal ruminal sac (Fig.43/14) disappeared at the level of 4th lumbar vertebra while the ventral one at junction between 4th and 5th lumbar vertebra.

In the caudal abdominal region, in 1st slice explained the ventral ruminal sac occupied the left side (Fig.39/2). The cecum (Fig.39/5) and proximal part of ascending colon located in the middle and dorsal third of the right side. The 2nd slice showed the rectum (Fig.39/10), body of uterus (Fig.39/11). and urinary bladder (Fig.39/12) appeared dorsal and ventral part filled with intestine. While in immature goat the urinary bladder (Fig.43/40) located at the ventral pelvic wall then rectum (Fig.43/43) and cecum (Fig.43/38) and intestine in dorsal part.

V. Computed Tomography of the abdomen

The results of our study included thirteen photo of C.T. images which arranged in three groups that explained the region of the abdomen the cranial, middle and caudal abdominal regions. Regarding the internal abdominal organs, their shape and tomography were varied according to the imaging position and scanning level, moreover the radio-density pattern of the visceral organs and large blood vessels increase in some scans than others.

C.T. image of the cranial abdominal region demonstrated that right and left caudal lobe of the lung which were low density and appear more clear in lung window, (Fig. 40/2&3) also aorta and left vena azygos (Fig.40/4&5) located between two diaphragmatic crura. The reticulum was an oval shaped structure, it had medium density (Fig.40/9). The dorsal ruminal sac observed as medium density in the ventral fourth part due to the presence of food and water and free density in upper three fourths due to presence the air, with scanning sequences, it was appeared between spleen to left and omasum liver to the right. Omasum was detected as circular or bean shaped structure with low density, located dorsomedial to the abomasum between the dorsal ruminal sac and liver. In lung window the omasal lamina demonstrated more obvious (Fig.40/f/15). Abomasum appeared as hypodensity mass in the ventromedial to dorsal ruminal sac and extending ventrally to rest on the ventral abdominal wall then shifted to right side (Fig.40/D/E&F/16). The ventral ruminal sac (Fig.40/E/19) was detected filled with food and fluid and had medium density. Liver appeared as the triangular shape with homogenous soft tissue. It presented in the right intrathoracic part of the abdominal cavity it presented between right abdominal wall and reticulum, with caudal scanning become presented between the dorsal ruminal sac, omasum and abomasum in left and the right lateral abdominal wall in right (Fig. 40/8). While the gall bladder visualized as elongated pear shaped structure on ventral part of the visceral surface of the liver, it had a homogenous lower density than that of the liver tissue.

The C.T. images in the middle abdominal region demonstrated that the dorsal and the ventral ruminal sac (Fig. 41/2&3), also the both the right and left longitudinal pillars detected (Fig. 41/14&15), and the caudal transverse pillars (Fig. 41/18) were clearly demonstrated at level of the beginning of the cecum scanning, and the dorsal ruminal sac end at the level of 5th lumbar vertebra. The small intestine (Fig.41/5) appeared as homogeneously hypodense highly convoluted band located in adjacent to the ventral ruminal sac. The distal loop of the ascending colon appeared as hypodense and characterized by presence of consecutive constrictions representing the fecal pellets inside (Fig.41/6). Descending colon was located dorsolateral to the left kidney and with caudal scan, it become near the medial plane and has characteristic folded mucosa (Fig.41/7). The proximal loop of the ascending colon represented by U-shape structure and has not folded mucosa presented in lateral part of the right and represented in middle and upper thirds of the right side (Fig.41/10). The spiral loop of ascending colon represented by scattered small circles and some of them had the folded mucosa (Fig.41/13). Cecum was scanned as circumscribed area to the right of rumen has contact with right abdominal wall (Fig.41/19). The kidneys; the right kidney (Fig.41/8) was scanned immediately caudal the liver highly dorsal in the abdominal cavity just ventral to the sublumbar muscles, while the left kidney (Fig.41/16) located right to median plane, it scanned caudal to the right one.

In the caudal abdominal region demonstrated that the caudoventral blind sac represented in the left side of abdomen (Fig.42/3), also the cecum and proximal part of ascending colon and small intestine occupied the right side of abdomen (Fig.42/4, 5&6) The urinary bladder (Fig.42/12) was visualized as a circular smooth contour structure with homogenous hypodensity, it was related to the cecum ventrally and uterine body (Fig.42/15) dorsally. Ovary was oval in shape with high density present medial to the shift

of the ilium (Fig.42/10). In the pelvic scan the rectum (Fig.42/9) was visualized dorsal to the uterine body (Fig.42/15).

VI. The surgical approach of the abdomen

The laparotomy performed in many sists, flank laparotomy, paramedian and midline laparotomy. In flank laparotomy, The incision made through skin, cutaneous trunci muscle, abdominal fascia, external abdominal oblique muscle, internal abdominal oblique muscle, transverse abdominal muscle, transverse abdominal fascia and peritoneum, if the incision in lower part of flank the incision will include dorsal part of the rectus abdominal muscle. In paramedian laparotomy, the incision made through the skin, cutaneous trunci muscle, abdominal fascia, outer layer of rectus sheath, rectus muscle, inner layer of rectus sheath, transverse abdominal fascia and peritoneum. In midline laparotomy the incision made through, skin, abdominal fascia, preputial or supramammary muscles , linea alba, transverse abdominal fascia and peritoneum.

Splenectomy: (Fig.44/3&46/C).

The spleen extends from upper fourth of the caudal border of 10th rib till the cranial end of transverse process 1st lumbar vertebra in left side. The incision 10 cm was made behind the last rib about 1 cm to avoid injury the costoabdominal nerve, artery and vein, in most cases required the resection to the last rib at 2-3 cm distal the vertebral end of the last rib to avoid the injury of the diaphragm. The incision passed via skin, cutaneous trunci muscle, abdominal fascia, external abdominal oblique muscle, serratus dorsalis caudalis muscle, part of internal abdominal oblique muscle at insertion with the last rib, retractor costae muscle aponeurosis of transverse abdominal muscle, transverse abdominal fascia and peritoneum.

Rumenotomy : (Fig.44/2).

It was ruminal fistula which used mainly for researches as adding drug or sucking the ruminal fluid. The site of incision presented in the left paralumbar fossa under the space between 2nd and 3rd transverse lumbar processes by about 2 cm, then made incision about 3 cm length, the incision passed through skin, cutaneous trunci muscle, abdominal fascia, external abdominal oblique muscle, the fleshy portion of transverse abdominal muscle , transverse abdominal fascia and peritoneum.

Rumenotomy: (Fig. 44/1&46/A).

The dorsal ruminal sac situated to the left of the median plane, at the level of 8th intercostal space and reached caudally till the level of 5th lumbar vertebra, the dorsal ruminal sac came in contact with the left paralumbar fossa .The site of rumenotomy under the space between 2nd and 3rd transverse lumbar process by 2-3cm then make incision about 12-15 cm in length The incision passed through the skin, cutaneous trunci muscle, external abdominal oblique muscle ,internal abdominal oblique muscle at lower two thirds of incision, the transverse abdominal muscle, transverse abdominal fascia and peritoneum

Left kidney: (Fig. 44/5&46/B).

The left kidney mainly occupied right to median plane under the transverse processes from 2nd to 4th lumbar vertebra. The incision 10 cm long was made in the left

paralumber fossa under the tip of 3rd lumbar transverse process by 2 cm, which will cut skin, cutaneous trunci muscle, external abdominal oblique, part of internal abdominal oblique muscle at lower half of the incision, transverse abdominal muscle (fleshy part), transverse abdominal fascia and peritoneum., then reflected the rumen to outside the left kidney will appear

Right kidney: (Fig. 45/1&46/D).

Right kidney occupied the right of the median plane extended from 12th intercostal space to the transverse process of 1st lumbar or 2nd lumbar vertebra. . The incision 10 cm was made behind the last right rib by 1 cm to avoid injury the costoabdominal nerve, artery and vein, The incision was passed via skin, cutaneous trunci muscle, abdominal fascia, external abdominal oblique muscle, serratus caudalis dorsalis muscle, part of internal abdominal oblique muscle at insertion with the last rib, retractor costae muscle, aponeurosis of transverse abdominal muscle, transverse abdominal fascia and peritoneum.

Liver: (Fig45/2&46/D).

The liver of goat was situated in the intrathoracic part of the abdominal cavity occupying the right hypochondriac region. Its long axis extended cranioventrally from the level of vertebral end of 13th rib up to ventral part of 6th intercostal space. the incision 10 cm was made behind the last right rib 1 cm to avoid injury the costoabdominal nerve, artery and vein, The incision passed via skin, cutaneous trunci muscle, abdominal fascia, external abdominal oblique muscle, serratus dorsalis caudalis muscle, part of internal abdominal oblique muscle at insertion with the last rib, retractor costae muscle, aponeurosis of transverse abdominal muscle, transverse abdominal fascia and peritoneum.

Gall bladder: (Fig. 45/3&46/E).

The gall ladder was pear in shape. It projected about 0.5 to 3.5 cm lower than the ventral hepatic border. It came in contact with right abdominal wall at ventral end of the 10th intercostal space. the incision 7 cm was made under the right costal arch at level of 10th intercostal space. The incision was passed via skin, cutaneous trunci muscle, abdominal tunic, abdominal fascia, outer layer of rectus sheath, dorsal part of the 3rd and 4th segments of rectus abdominal muscle, inner layer of rectus sheath, , transverse abdominal fascia and peritoneum.

Abomasum displacement (Fig. 45/5).

The incision was made 10 cm long which parallel to the right costal arch and dorsal to cranial superficial epigastric vein and artery. The incision was passed via skin, cutaneous trunci muscle, abdominal tunic, outer layer of rectus sheath, dorsal part of the 3rd and 4th segments of rectus abdominal muscle, inner layer of rectus sheath, transverse abdominal muscle, transverse abdominal fascia and peritoneum.

Cecum: (Fig.45/4&46/F).

It located against the right paralumber fossa separated from it by the greater omentum. It located in the dorsal caudal two thirds of the abdominal cavity which extended from the 3rd or 4th lumbar vertebra till the pelvic inlet. Incision was made 10 cm long in the right paralumber fossa under the tip of 4th lumbar transverse process by 8-10

cm, which will cut skin, cutaneous trunci muscle, abdominal fascia, external abdominal oblique muscle, internal abdominal oblique muscle, transverse abdominal muscle, transverse abdominal fascia, peritoneum and greater omentum

Caesarean operation: (Fig.44/4).

There were many sites for surgical approach to uterus, they were vertical incision in lower flanks, right and left; paramedian incision in which the animal in recumbence position and performed by incision 15 cm was made in lateral to midline by 5 cm and parallel to caudal superficial epigastric artery and vein and just cranial the udder and the third site at the midline which the animal in recumbence position incision 15 cm was made in linea alba and just cranial the udder, the best site was at the left flank, the animal in standing position which made vertical incision under 4th lumbar transverse process by 10 – 13cm which while include skin, cutaneous trunci muscle, abdominal fascia small part of fleshy and large part of aponeurosis of external abdominal and internal abdominal muscles, part of rectus abdominal muscle (last segment) and aponeurosis of transverse abdominal muscle and transverse abdominal fascia and peritoneum. The site was best due to the control of rumen at left side was easily than the control intestine in right flank region with uterine horns and better than the paramedian to avoid bleeding from caudal superficial epigastric artery and vein.

Hernia:

The occurrence of hernia may be umbilical hernia, ventral and lateral abdominal hernia and inguinal hernia. In umbilical hernia made elliptical incision then push the hernial sac into peritoneal cavity then suture the linea alba and skin. In ventral abdominal hernia after pushing the hernial sac, must suture inner layer of rectus sheath, rectus abdominal muscle and outer layer of rectus sheath, cutaneous trunci muscle and skin, in lateral abdominal hernia after pushed hernial sac, we must suture transverse abdominal muscle and fascia, the internal and external abdominal oblique muscles, cutaneous trunci muscle and skin. In inguinal hernia make elliptical incision in skin around the scrotum, removal testes and closure the superficial inguinal ring and skin

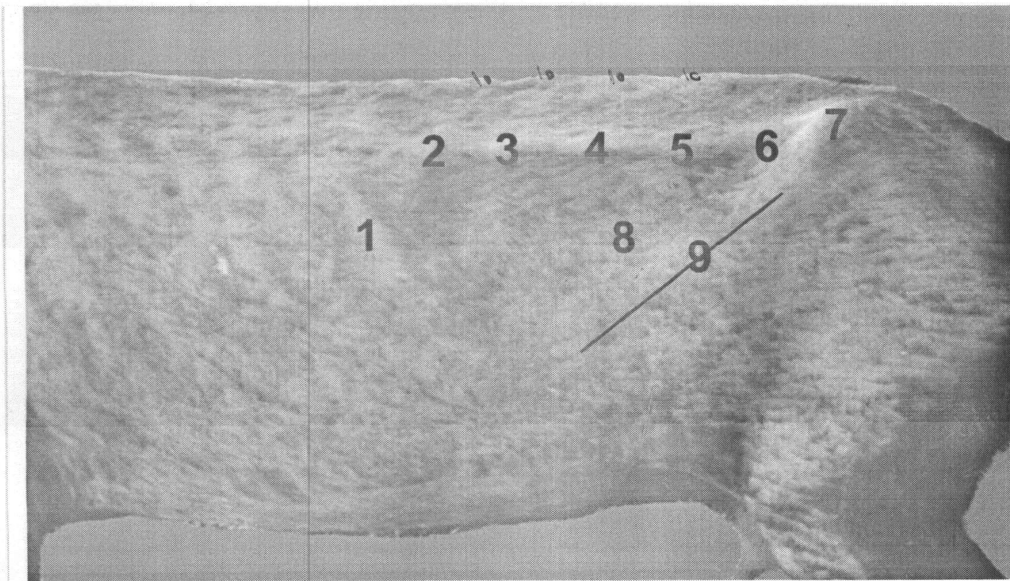
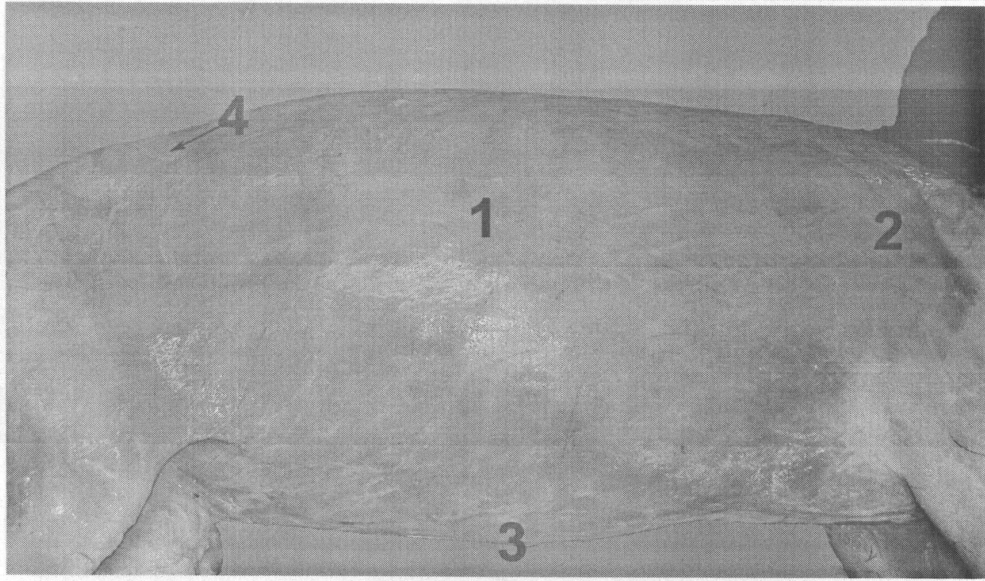


Fig. (2): Lateral view of the abdomen of goat, explained the paralumbar fossa:

1. Last rib.
2. Transverse process of 2nd lumbar vertebra.
3. Transverse process of 3rd lumbar vertebra.
4. Transverse process of 4th lumbar vertebra.
5. Transverse process of 5th lumbar vertebra.
6. Transverse process of 6th lumbar vertebra.
7. Tuber coxae.
8. Paralumbar fossa.
9. Ridge of the internal abdominal oblique muscle.
10. Spinous processes of lumbar vertebrae.



Fig, (3): Superficial dissection of the abdominal wall of the goat (Right lateral view).

1. Cutaneous trunci muscle.
2. Cutaneous omobrachialis muscle.
3. Supramammary muscle.
4. Aponeurosis of the cutaneous trunci muscle.

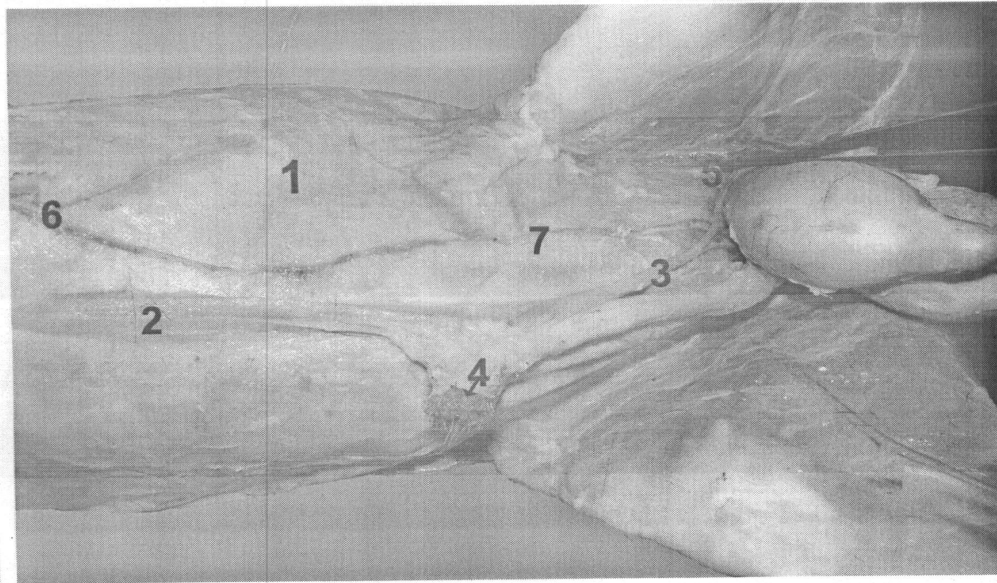


Fig. (4): Superficial dissection of the abdominal wall of the buck (ventrolateral view).

1. Cutaneous trunci muscle.
2. Cranial preputial muscle.
3. Caudal preputial muscle.
4. Preputial orifice.
5. Superficial inguinal ring.
6. Cranial superficial epigastric artery and vein.
7. Caudal superficial epigastric artery and vein.

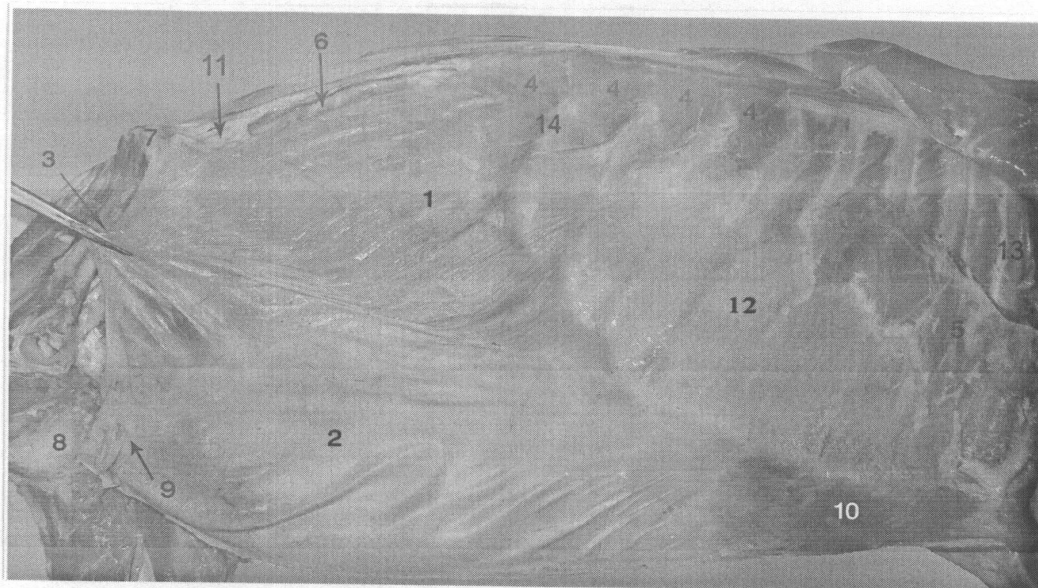


Fig. (5): Right view of the abdominal wall of the goat.

1. External abdominal oblique muscle (fleshy part):
2. Aponeurosis of external abdominal oblique muscle.
3. Inguinal ligament.
4. Serratus dorsalis caudalis muscle.
5. Serratus ventralis thoracis muscle.
6. Transverse abdominal muscle.
7. Tuber coxae.
8. Pelvic symphysis.
9. Superficial inguinal ring.
10. External rectus sheath in epigastric region (enlarged in next figure).
11. Origin of internal abdominal oblique muscle.
12. Abdominal tunic.
13. 6th rib.
14. Last rib.




Fig. (6): Enlarged part of external rectus sheath at the epigastric region, show the arrangement of the aponeurosis of external and internal abdominal oblique muscles.

1. Aponeurosis of external abdominal oblique muscle.
2. Aponeurosis of internal abdominal oblique muscle.
3. External abdominal oblique muscle (fleshy part).
4. Tendon of the rectus abdominal muscle.

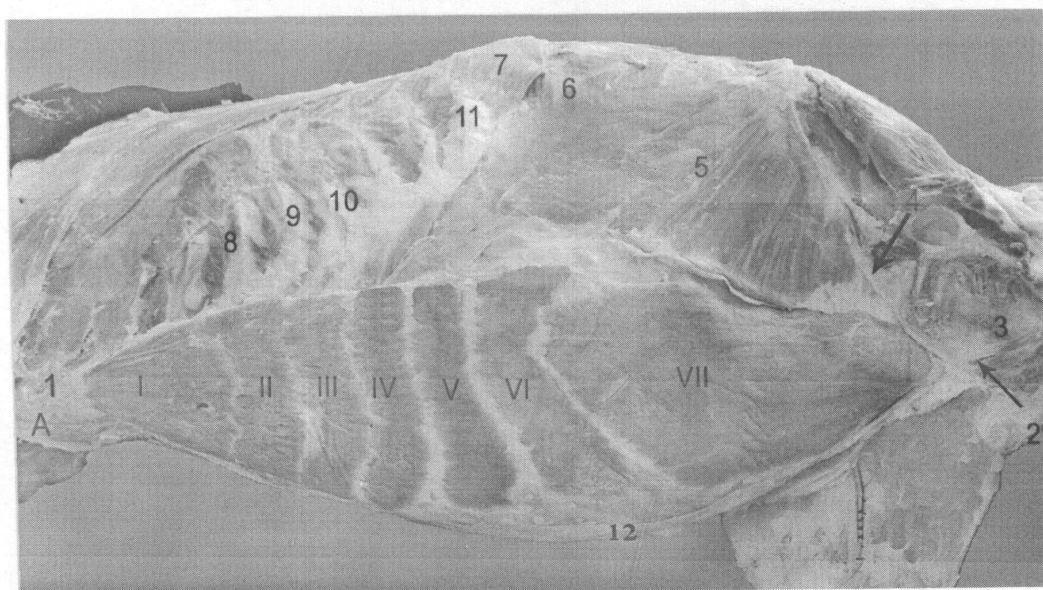


Fig. (7): Left lateral view abdominal wall in the goat explained the abdominal muscles.

1. Tendon of the rectus abdominal muscle.
 2. Prepubic tendon.
 3. Pelvic symphysis.
 4. Inguinal ligament.
 5. Internal abdominal oblique muscle.
 6. Transverse abdominal muscle.
 7. Serratus dorsalis caudalis muscle.
 8. 8th rib.
 9. 9th rib.
 10. 10th rib.
 11. Last rib.
 12. linea alba
- A. Sternum.
 I. to VII. The segments of rectus abdominal muscle from 1st to 7th segment.

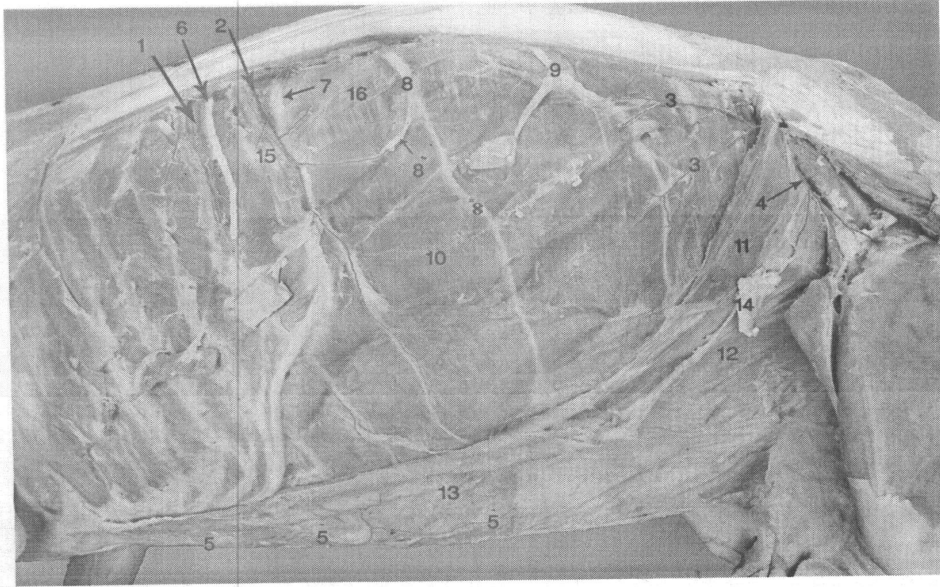

Fig. (8): Lateral view of abdominal wall of goat explained its arteries and nerves.

1. Last intercostal artery.
2. Costoabdominal artery.
3. Cranial branches of the deep circumflex artery.
4. Caudal branch of the deep circumflex artery.
5. Cranial epigastric artery.
- 5'. Cranial superficial epigastric artery.
6. Last intercostal nerve.
7. Costoabdominal nerve.
8. Iliohypogastric nerve.
- 8'. Lateral branch of iliohypogastric nerve
- 8". medial branch of iliohypogastric nerve
9. Ilioinguinal nerve.
10. Transverse abdominal muscle.
11. Internal abdominal oblique muscle.
12. External abdominal oblique aponeurosis and abdominal tunic.
13. Cutaneous trunci muscle.
14. Subiliac lymph node.
15. Last rib.
16. Lumbar triangular aponeurosis of transverse abdominal muscle.

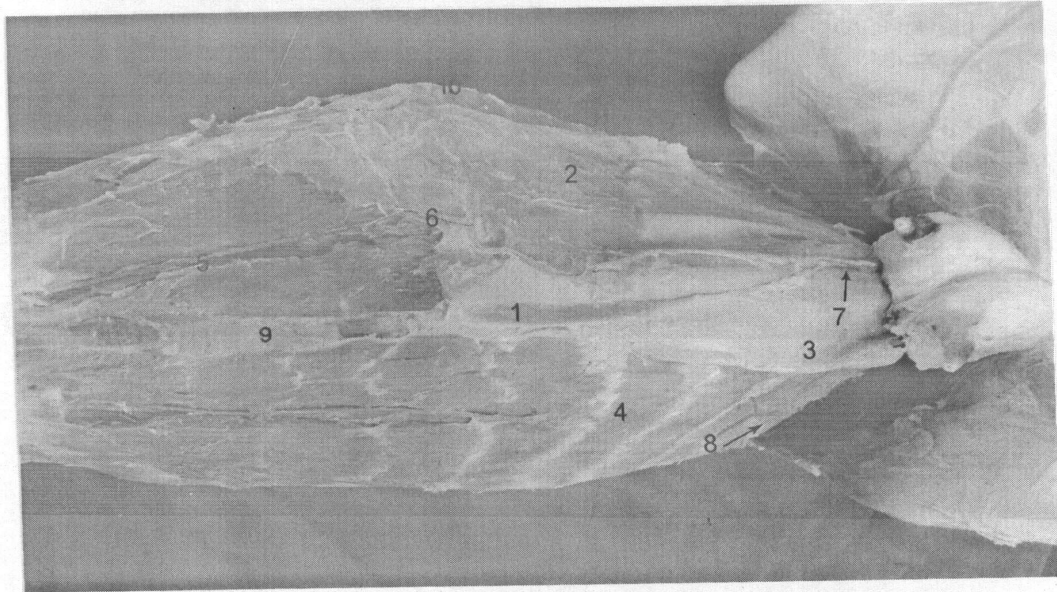


Fig. (9): Ventral view of the abdominal wall.

1. Supramammary muscle (left band).
2. Cutaneous trunci muscle.
3. Aponeurosis of external abdominal oblique muscle.
4. Rectus abdominal muscle.
5. Cranial epigastric artery.
6. Cranial superficial epigastric artery.
7. Caudal superficial epigastric artery.
8. Caudal epigastric artery.
9. Xiphoid cartilage.
10. Last rib.

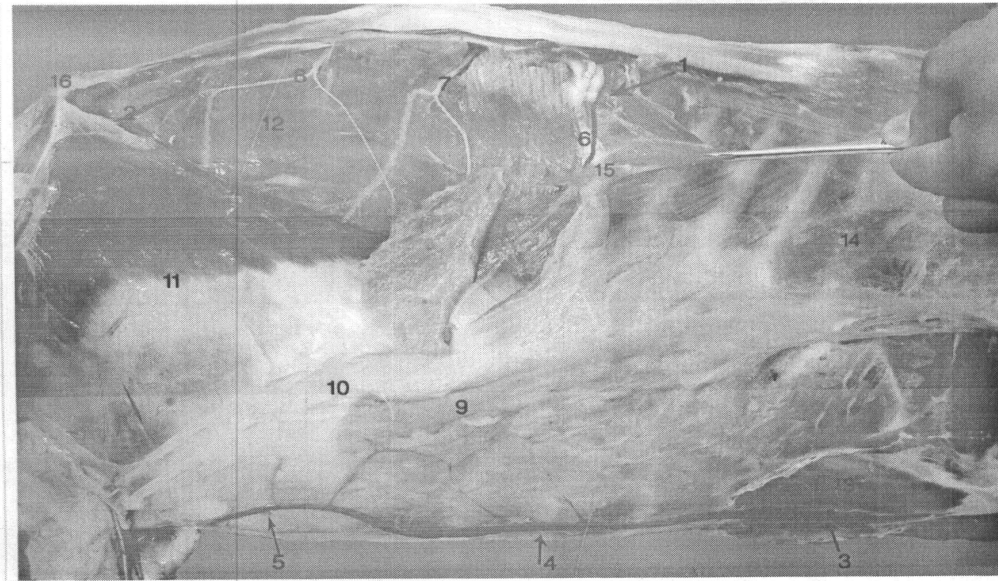


Fig. (10): Right lateral view the abdominal wall of goat explained its veins.

1. Costoabdominal vein.
2. Cranial circumflex vein.
3. Cranial epigastric vein.
4. Cranial superficial epigastric vein.
5. Caudal superficial epigastric vein.
6. Costoabdominal nerve.
7. Iliohypogastric nerve.
8. Ilioinguinal nerve.
9. Cutaneous trunci muscle.
10. Tunica flava and aponeurosis of external abdominal oblique muscle.
11. Internal abdominal oblique muscle.
12. Transverse abdominal muscle.
13. Rectus abdominal muscle.
14. 9th rib.
15. Last rib.
16. Tuber coxice.

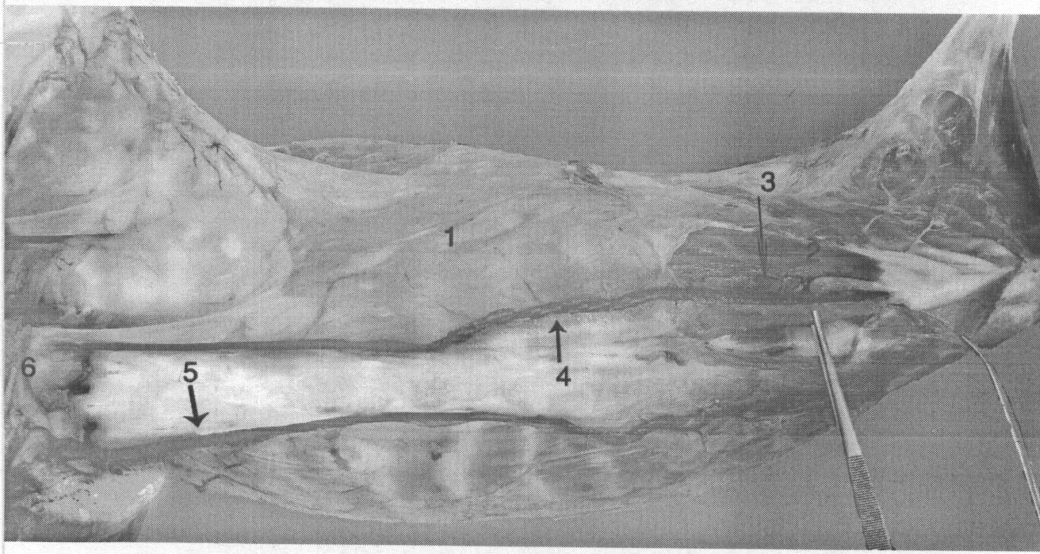


Fig. (11): Ventral view abdominal wall explained its venous drainage.

1. Cutaneous trunci muscle.
2. Rectus abdominal muscle.
3. Cranial epigastric vein.
4. Cranial superficial epigastric vein.
5. Caudal superficial epigastric vein
6. Udder.

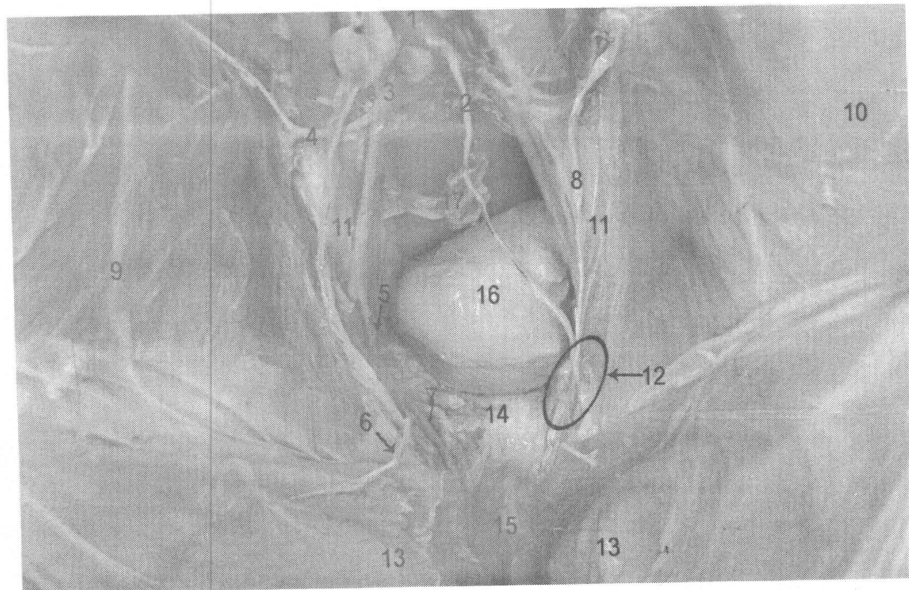


Fig. (12): Abdominal cavity (caudal part):

1. Abdominal aorta.
2. Testicular artery.
3. External iliac artery.
4. Deep circumflex artery.
5. Pudendoepigastric artery.
6. Caudal epigastric artery.
7. External pudendal artery.
8. Genitofemoral nerve.
9. Caudal branch of ilioinguinal nerve.
10. Internal abdominal oblique muscle.
11. Cremaster muscle.
12. Deep inguinal ring.
13. Rectus abdominal muscle.
14. Cranial border of the pubic bone.
15. Prepubic tendon.
16. Urinary bladder.
17. Rectum.

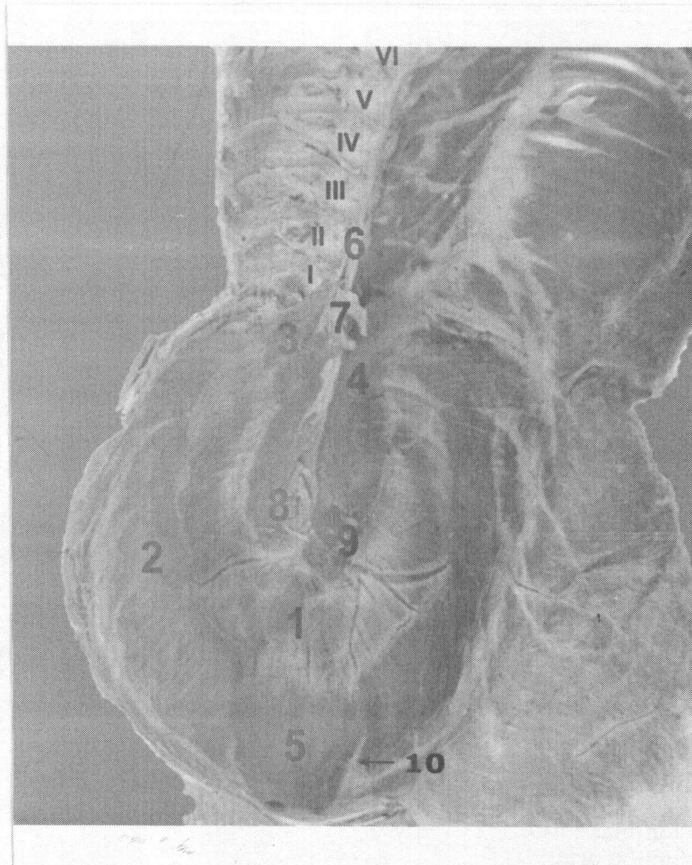


Fig. (13): Caudal view of the diaphragm.

1. Central tendinous part.
 2. Costal part.
 3. Left crus.
 4. Right crus.
 5. Sternal part.
 6. Common tendon.
 7. Aortic hiatus.
 8. Esophageal hiatus.
 9. foramen vena cava.
 10. Fibrous band.
- I to VI. Number of lumbar vertebrae.

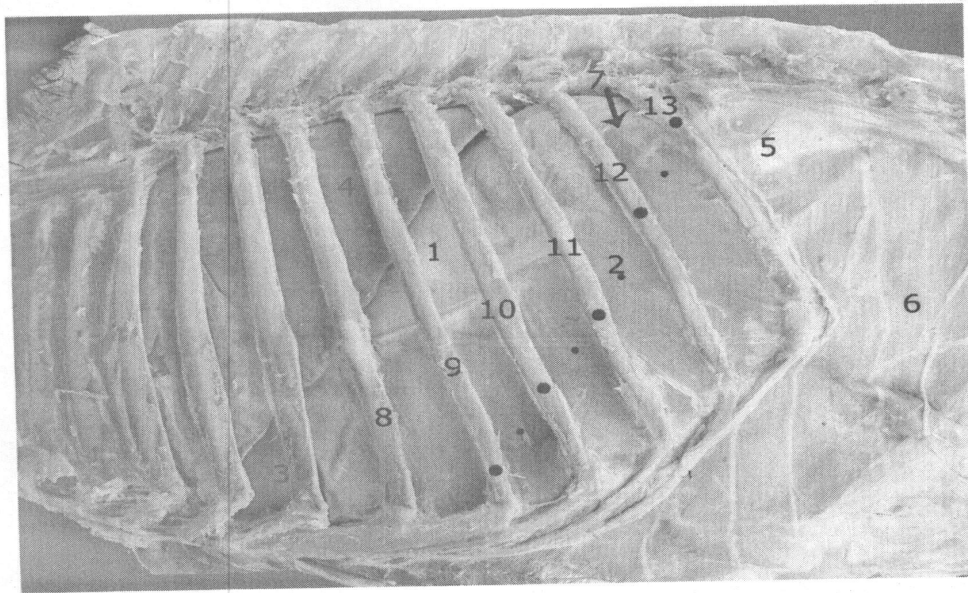


Fig. (14): Left lateral view of the thorax and abdomen showed, the costal attachment of the diaphragm by the dotted line.

1. Central tendinous part of diaphragm.
2. Costal part.
3. Sternal part.
4. Caudal left lobe of the lung.
5. Triangular aponeurosis of the transverse abdominal.
6. Transverse abdominal muscle.
7. Site puncture of spleen.
- 8-13. Number of ribs from 8th to 13th rib.

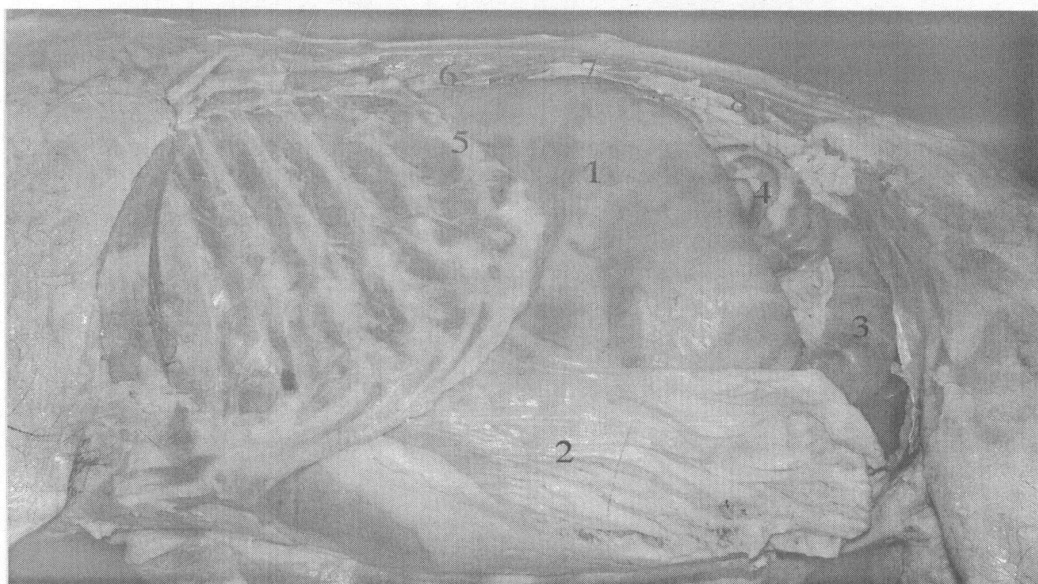

Fig. (15): Left lateral view of the abdomen of the goat.

1. Dorsal ruminal sac.
2. Superficial layer of greater omentum
3. Cecum
4. Spiral loop of ascending colon
5. Last rib
6. 1st lumbar transverse process
7. 3rd lumbar transverse process
8. 5th lumbar transverse process

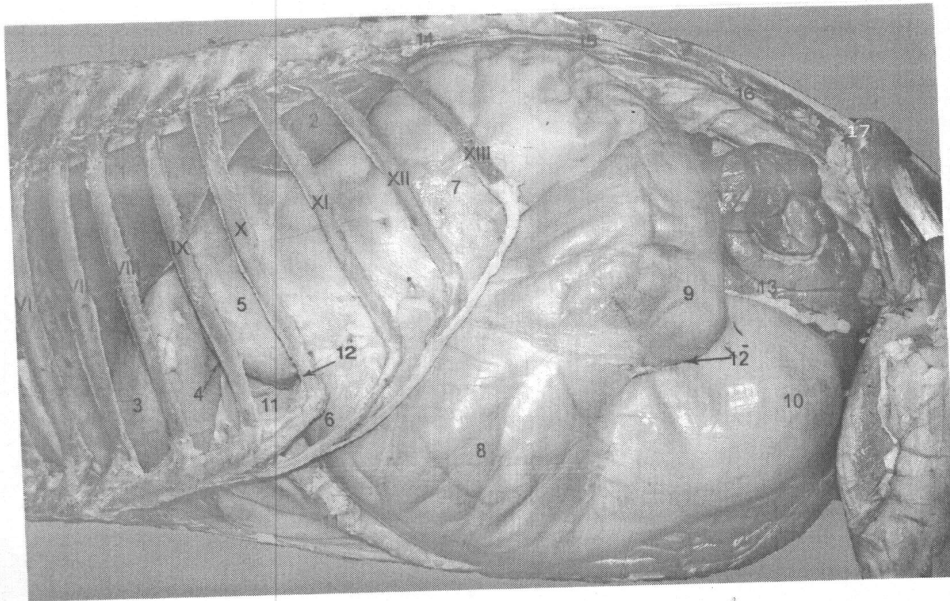


Fig. (16): Left lateral view explained the topography of the abdominal organs of the goat (omentum was removed)

1. Left caudal lobe of the lung.
2. Spleen.
3. Reticulum.
4. Ruminoreticular groove.
5. Ruminal atrium.
6. Ruminal recess.
7. Dorsal ruminal sac.
8. Ventral ruminal sac.
9. Caudodorsal blind sac.
10. Caudoventral blind sac.
11. Abomasum.
12. Cranial transverse groove.
- 12' Caudal transverse groove.
13. Intestine.
14. 1st lumbar transverse process.
15. 3rd lumbar transverse process.
16. 5th lumbar transverse process.
17. Tuber coxae.

VI TO XIII Ribs number from 6th to 13th rib.

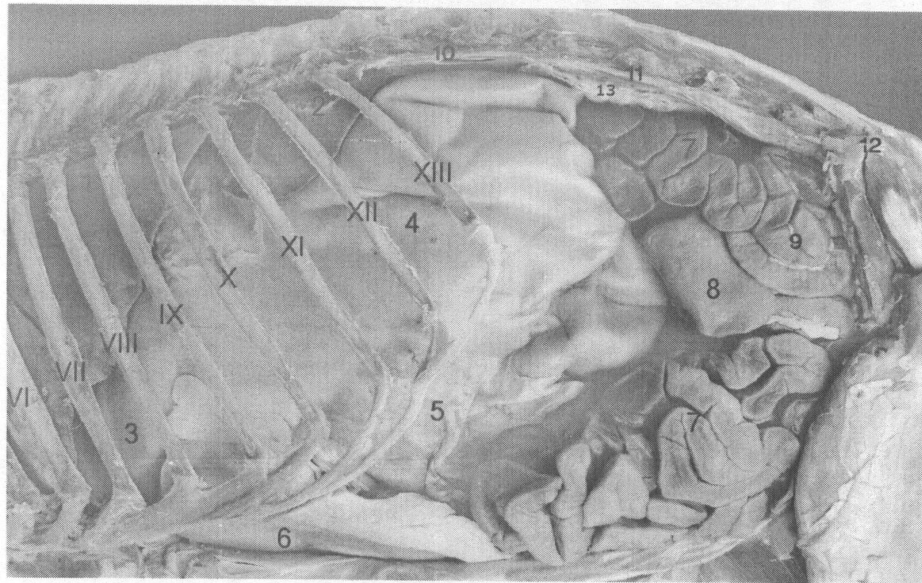


Fig. (17): Left lateral view of the abdomen explained the abdominal organs in goat which was fasted 48 hrs.

1. Caudal lobe of the lung.
2. Spleen.
3. Reticulum.
4. Dorsal ruminal sac.
5. Ventral ruminal sac.
6. Abomasum.
7. Intestines (Jejunum).
8. Blind end of the cecum
9. Spiral colon.
10. 2nd lumbar transverse process.
11. 4th lumbar transverse process.
12. Tuber coxae.
13. Left kidney

VI TO XIII Ribs numbers from 6th to 13th rib

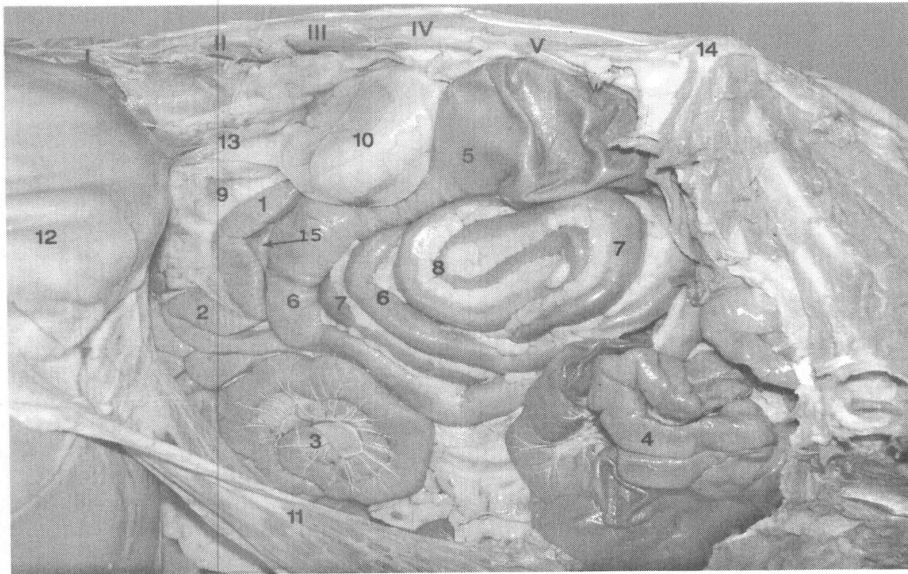


Fig. (18): The left lateral view explained the topography of the abdominal organs (Rumen was reflected):

1. Ascending duodenum.
 2. Duodenojejunal flexure.
 3. Circular shape of the jejunum.
 4. Jejunum.
 5. Proximal loop of the ascending colon.
 6. Centripetal gyri.
 7. Centrifugal gyri.
 8. Central flexure.
 9. Duodenocolic ligament.
 10. Left kidney.
 11. Superficial wall of the greater omentum.
 12. Visceral surface of the rumen.
 13. Descending colon.
 14. Tuber coxae
 15. distal loop of ascending colon
- I to V Numbers of lumbar transverse processes of the from 1st to 5th.

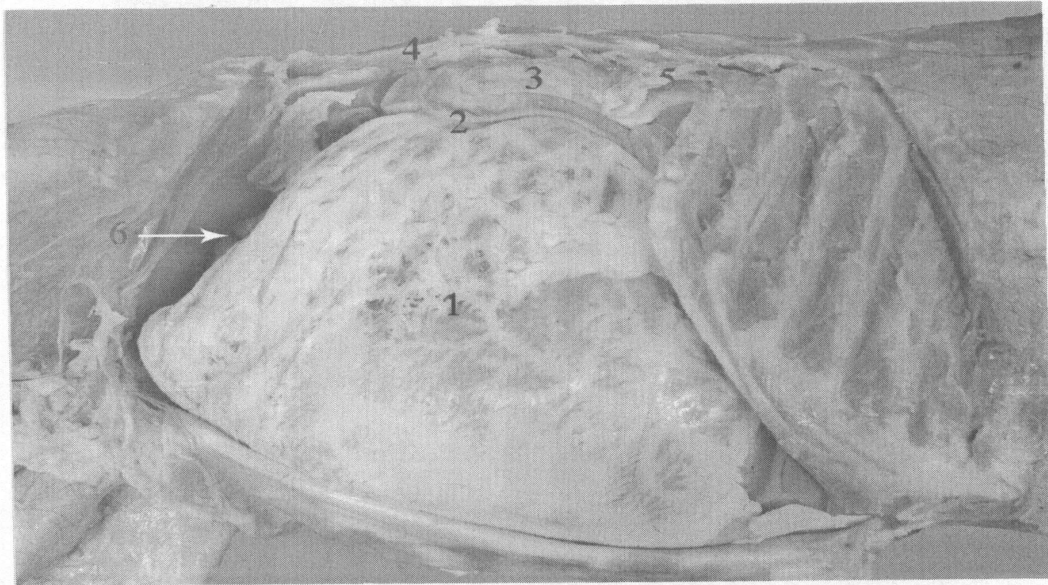


Fig. (19): Right lateral view of the abdomen

1. Greater omentum
2. Descending duodenum
3. mesoduodenum
4. 4th lumbar transverse process
5. Last rib
6. Supraomental recess

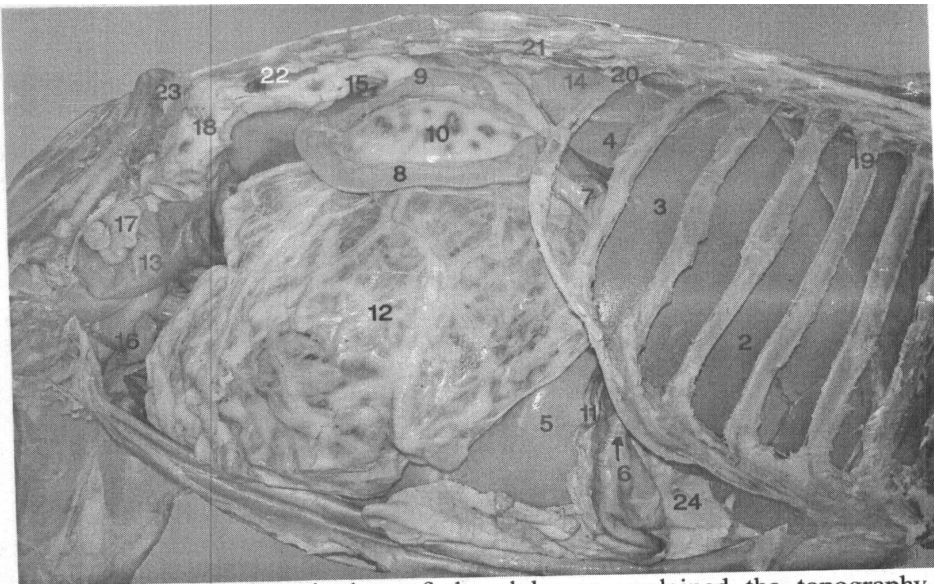


Fig. (20): Right dorsolateral view of the abdomen explained the topography of the abdominal organs.

1. Left lobe of the liver.
2. Quadrate lobe of the liver.
3. Right lobe of the liver.
4. Caudate process of the liver.
5. Ventral ruminal sac.
6. Abomasum (pyloric part).
7. Cranial part of the duodenum.
8. Descending duodenum.
9. Ascending duodenum.
10. Mesoduodenum.
11. Superficial layer of the greater omentum.
12. Deep layer of the greater omentum.
13. Cecum.
14. Right kidney.
15. Descending colon.
16. Jejunum.
17. Uterine horn.
18. Sigmoid flexure of descending colon.
19. 9th rib.
20. Last rib.
21. 2nd transverse lumbar transverse process.
22. 5th lumbar transverse process.
23. Tuber coxae.
24. lesser omentum

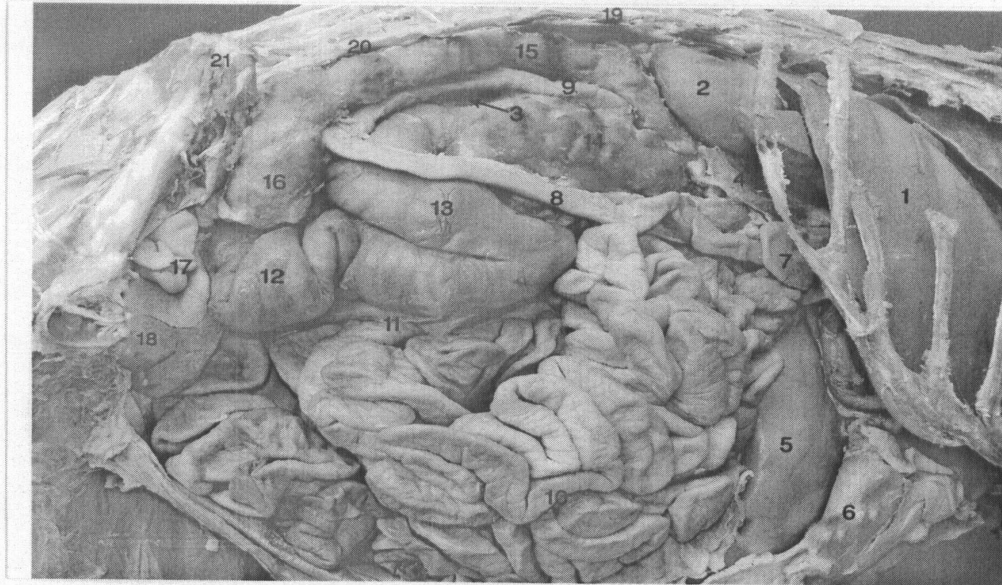


Fig. (21): Right dorsolateral view of the abdomen, showed the topography of the abdominal organs (Removed greater omentum).

1. Liver.
2. Right kidney.
3. Left kidney.
4. Pancreas (Right lobe).
5. Ventral ruminal sac.
6. Abomasum.
7. Cranial part of duodenum (flexure).
8. Descending duodenum.
9. Ascending duodenum.
10. Jejunum.
11. Ilium.
12. Cecum.
13. Proximal loop of ascending colon.
14. Distal loop of colon ascending colon.
15. Descending colon.
16. Sigmoid flexure of the descending colon .
17. Uterine horn.
18. Urinary bladder.
19. 2nd lumbar transverse process.
20. 5th lumbar transverse process.
21. Tuber coxae.

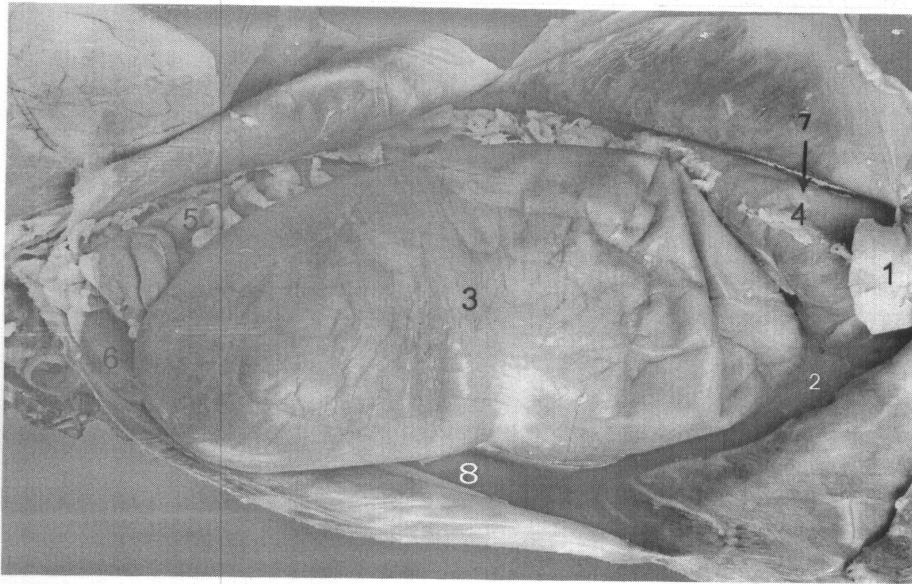


Fig. (22): The ventral view of the abdomen, explained the abdominal organs of the goat.

1. Xiphoid cartilage.
2. Reticulum.
3. Ventral ruminal sac.
4. Abomasum (body).
5. Intestine.
6. Cecum.
7. Site of the puncture of the abomasum.
8. Dorsal ruminal sac.




Fig. (23): Right lateral view of the abdomen explained the topography of the liver.

1. Caudate process.
 2. Right lobe of the liver.
 3. Quadrate lobe of the liver.
 4. Left lobe of the liver.
 5. Gall bladder.
 6. Right kidney.
 7. Diaphragm.
 8. Right caudal lobe of the lung.
 9. Greater omentum (superficial layer).
 10. & 10' biopsy Sites of the liver.
 11. Descending duodenum.
 12. Lesser omentum.
 13. Abomasum.
- From **VI** to **XIII** ribs number from 6th to 13th rib.

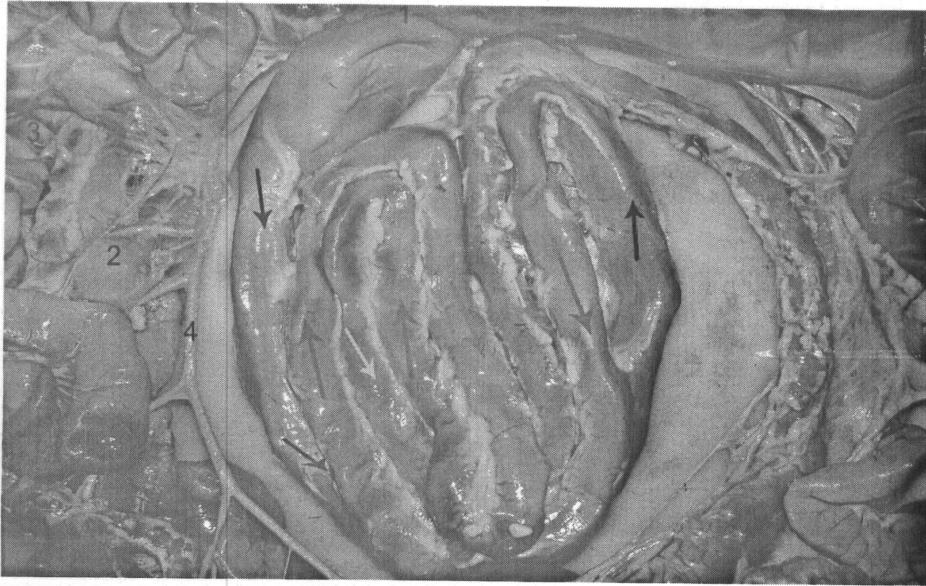


Fig. (24): Spiral loop of ascending colon showed the special arrangement of the centripetal and centrifugal gyri.

1. Proximal part of the ascending colon.
2. Jejunal lymph node.
3. Jejunum.
4. Cranial mesenteric artery.
 - Black arrow refers to centripetal.
 - Red arrow refers to centrifugal.
 - Yellow arrow refers to centripetal.
 - Blue arrow refers to centrifugal.

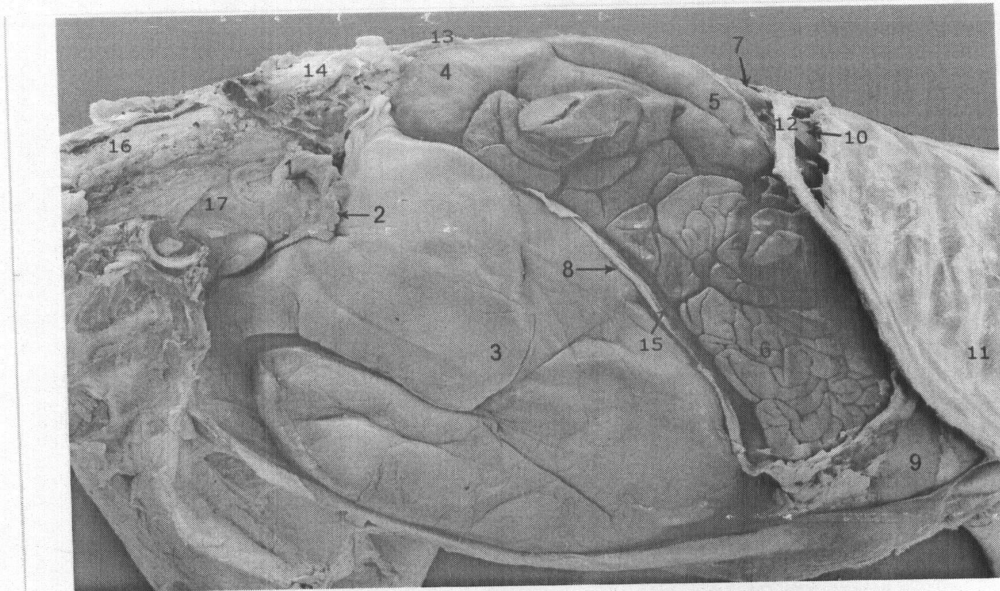


Fig. (25): Right lateral view of the pelvis and abdomen explained the topography of the abdominal and pelvic organs in the pregnant goat (four months).

1. Ovary.
2. Uterine tube.
3. Gravid uterine horn.
4. Cecum.
5. Proximal loop of the ascending colon.
6. Jejunum.
7. Descending duodenum.
8. Greater omentum.
9. Abomasum.
10. Caudate process of the liver.
11. 9th costochondral junction.
12. Last rib.
13. 5th lumbar transverse process.
14. Tuber coxae.
15. supraomental recess
16. rectum
17. uterine body

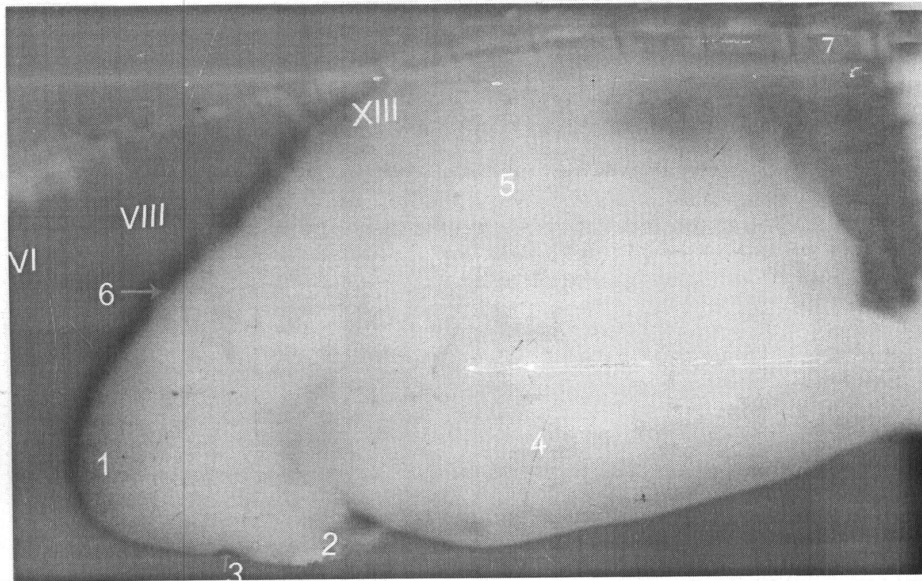


Fig. (26): Lateral abdominal radiograph of the goat gastrointestinal tract after 20 minutes of barium administration.

1. Reticulum.
2. Abomasum (fundus).
3. Ruminoreticular groove.
4. Ventral ruminal sac.
5. Dorsal ruminal sac.
6. Diaphragm.
7. 5th lumbar vertebra
- VI. 6th rib.
- VIII. 8th rib.
- XIII. 13th rib

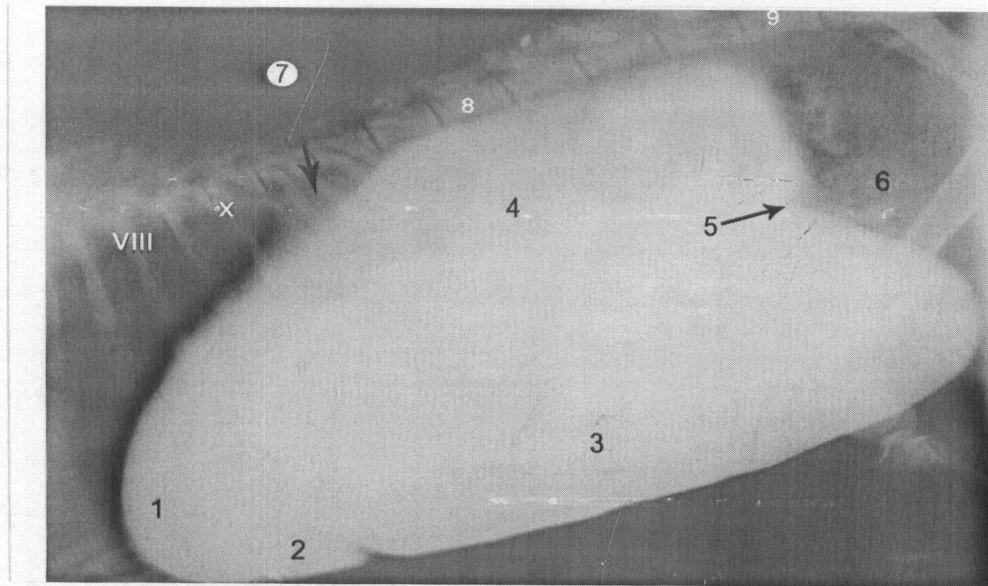


Fig. (27): Lateral abdominal radiograph showed the position of the goat gastrointestinal tract after 1 hrs of barium administration.

1. Reticulum.
2. Abomasum.
3. Ventral ruminal sac.
4. Dorsal ruminal sac.
5. Caudal transverse pillar or groove.
6. Intestine.
7. Spleen.
8. 1st lumbar vertebra.
9. 5th lumbar vertebrae.
- VIII. 8th rib.
- XI. 10th rib.

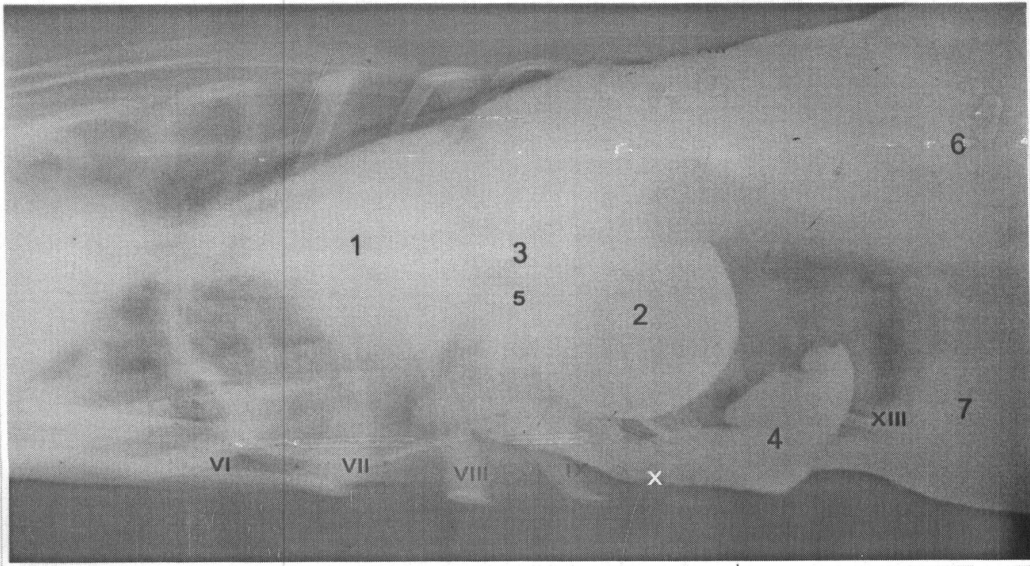


Fig. (28): Ventrodorsal view of abdominal radiograph explained goat stomach after 1 hrs of barium administration.

1. Reticulum.
 2. Omasum.
 3. Reticuloomasal opening.
 4. Abomasum.
 5. Omasoabomasal opening.
 6. Dorsal ruminal sac.
 7. Ventral ruminal sac.
- From VI to XIII. Number of costal cartilages.

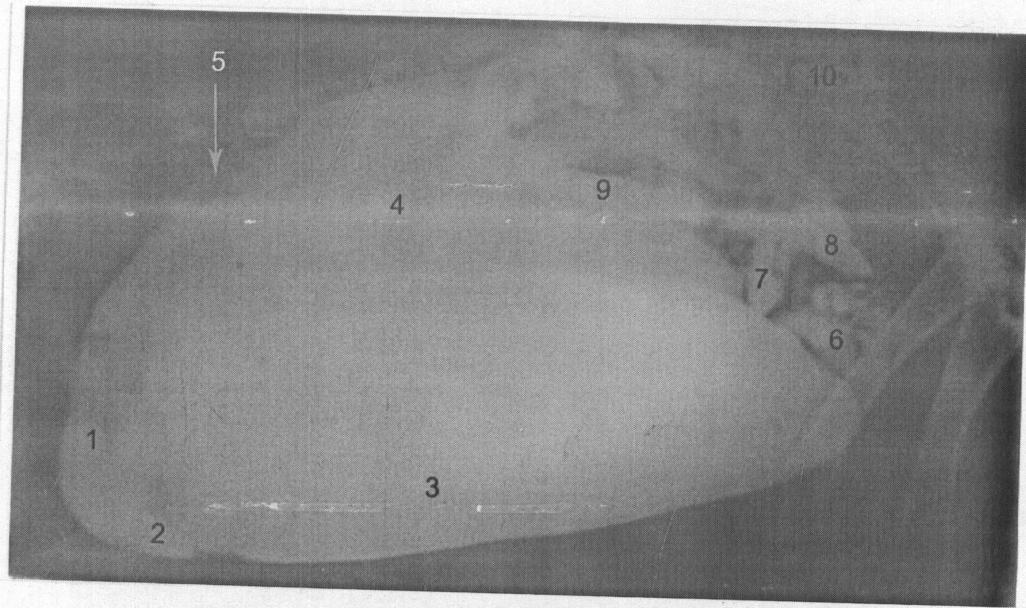


Fig. (29): Lateral abdominal radiograph showed the position of the various part of the goat gastrointestinal tract after 4 hrs of barium administration.

1. Reticulum.
2. Fundus of abomasum.
3. Ventral ruminal sac.
4. Dorsal ruminal sac.
5. Spleen.
6. Small intestine.
7. Ileum.
8. Cecum (Filling).
9. Proximal loop of ascending colon.
10. 6th lumbar vertebra.

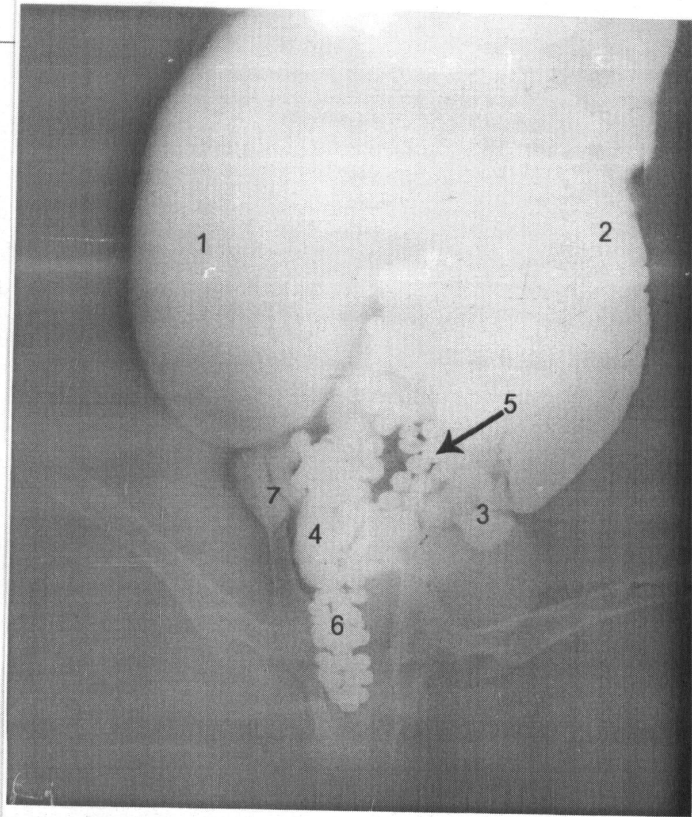


Fig. (30): The ventrodorsal view of abdominal radiograph showed the position of the gastrointestinal tract of goat after 24 hrs of barium administration.

1. Dorsal ruminal sac.
2. Ventral ruminal sac.
3. Small intestine.
4. Cecum.
5. Sigmoid flexure of the descending colon.
6. Rectum.
7. Ascending colon.

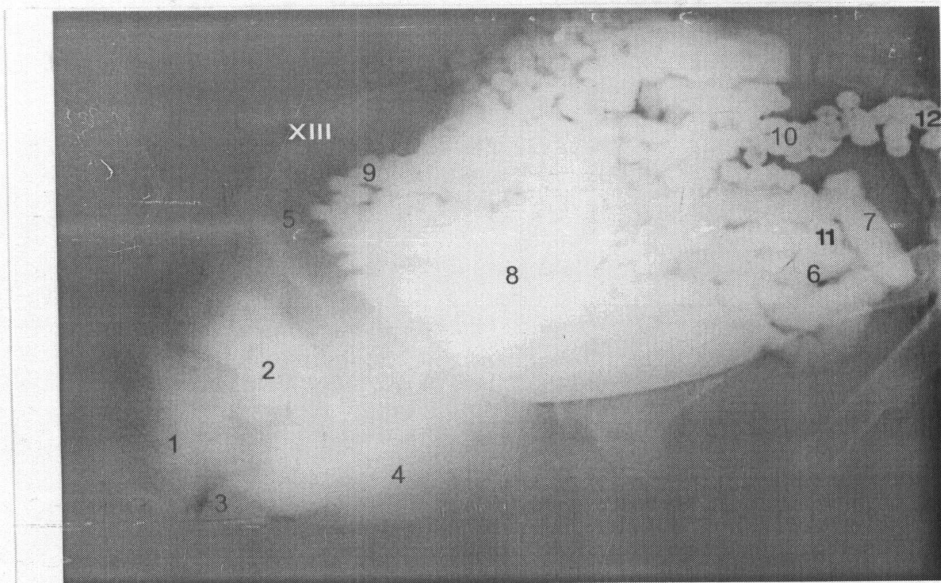


Fig. (31): Lateral abdominal radiograph showed the position of gastrointestinal tract of the goat at 24 hr of barium administration.

1. Reticulum.
2. Omasum.
3. Abomasum.
4. Ventral ruminal sac.
5. Dorsal ruminal sac.
6. Small intestine.
7. Cecum.
8. Spiral colon.
9. Transverse colon.
10. Sigmoid flexure of descending colon.
11. Ileum.
12. Rectum.
- XIII. 13th rib

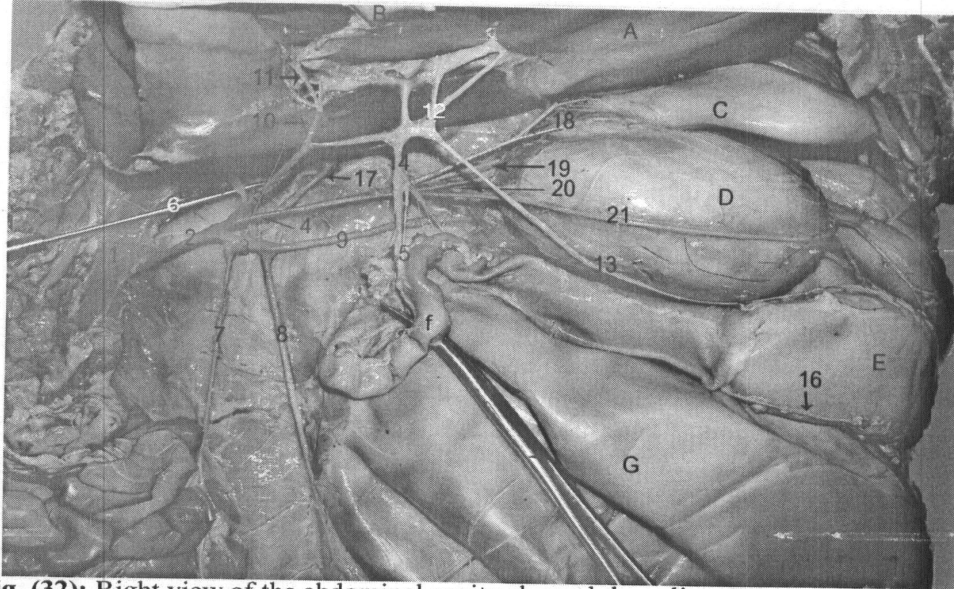


Fig. (32): Right view of the abdominal cavity showed the celiac artery.

1. Abdominal aorta.
 2. Celiac artery.
 3. Splenic artery.
 4. Left gastric artery.
 5. Hepatic artery.
 6. Splenic branch.
 7. Epiploic artery.
 8. Right ruminal artery.
 9. Left ruminal artery.
 10. Right hepatic artery.
 11. Cystic artery.
 12. Left hepatic artery.
 13. Right gastric artery.
 14. Gastroduodenal artery.
 15. Cranial pancreaticoduodenal artery.
 16. Right gastroepiploic artery.
 17. Reticular artery.
 18. Accessory reticular artery.
 19. Left gastroepiploic artery.
 20. Omasal branch.
 21. Left gastric artery.
- A. Liver.
 B. Gall bladder.
 C. Reticulum.
 D. Omasum.
 E. Abomasum.
 F. Ventral ruminal sac.
 G. Duodenum.

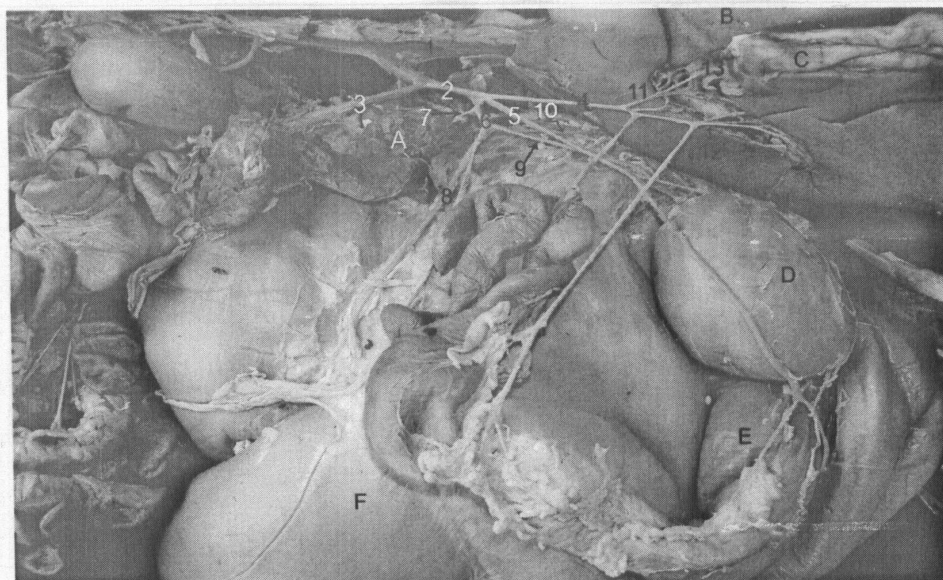


Fig. (33): Right view of the abdominal cavity showed the celiac artery.

1. Abdominal aorta.
 2. Celiac artery.
 3. Cranial mesenteric artery.
 4. Hepatic artery.
 5. Left gastric artery.
 6. Splenic artery.
 7. Pancreatic branch.
 8. Right ruminal artery.
 9. Left ruminal artery.
 10. Reticular artery.
 11. Right hepatic artery.
 12. Left hepatic artery.
 13. Cystic artery.
- A. Pancreas.
 - B. Liver.
 - C. Gall bladder.
 - D. Omasum.
 - E. Abomasum.
 - F. Ventral ruminal sac.

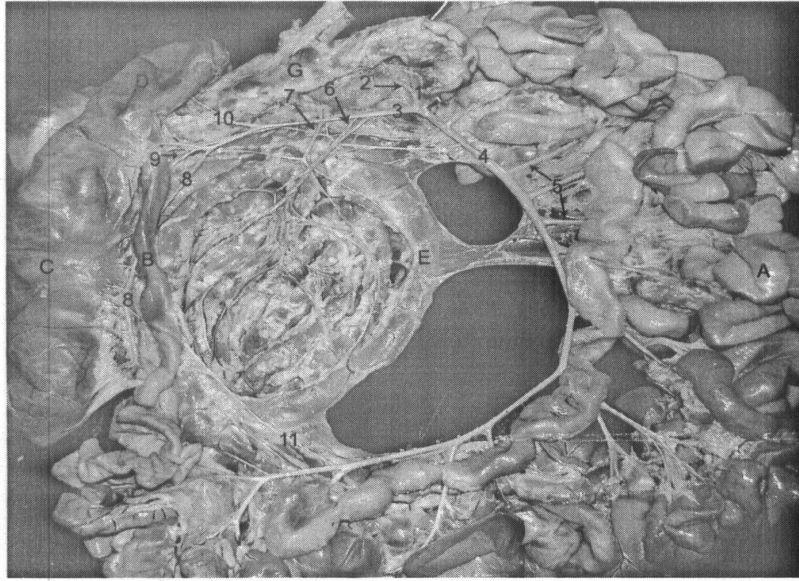


Fig. (34): Right lateral of intestine explained the cranial mesenteric artery.

1. Cranial mesenteric artery.
2. Middle colic artery.
3. Ileocecal artery.
4. Continuation of cranial mesenteric artery.
5. Jejunal arteries.
6. Colic artery.
7. Right colic artery.
8. Cecal artery.
9. Mesenteric ileal branch.
10. Branches to proximal part of ascending colon.
11. Ileal branch.
 - A. Jejunum.
 - B. Ileum.
 - C. Cecum.
 - D. Proximal loop of ascending colon.
 - E. Centripetal gyrus.
 - F. Distal loop of ascending colon.

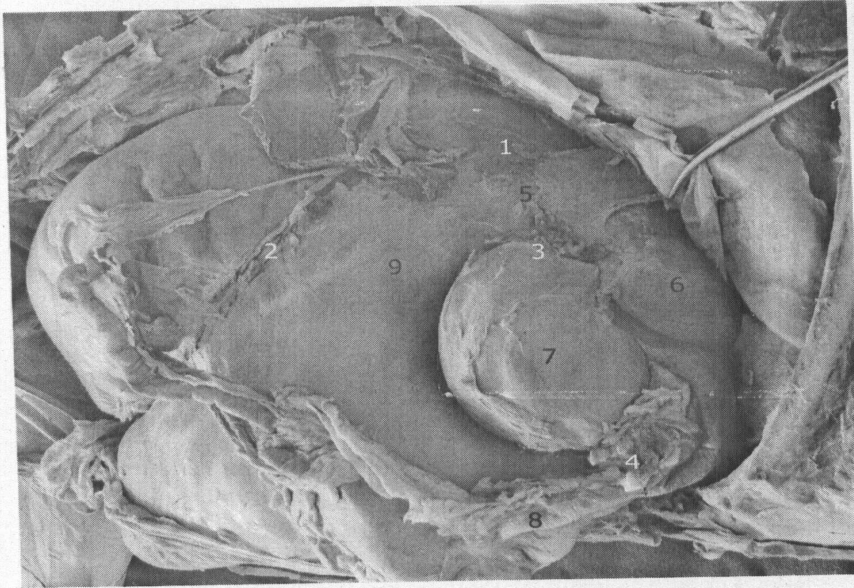


Fig. (35): Right lateral view of goat stomach explained their celiac lymphocenter.

1. Atrial lymph nodes.
2. Right ruminal lymph nodes.
3. Omasal lymph nodes.
4. Dorsal abomasal lymph node.
5. Cardia.
6. Reticulum.
7. Omasum.
8. Abomasum.
9. Rumen.

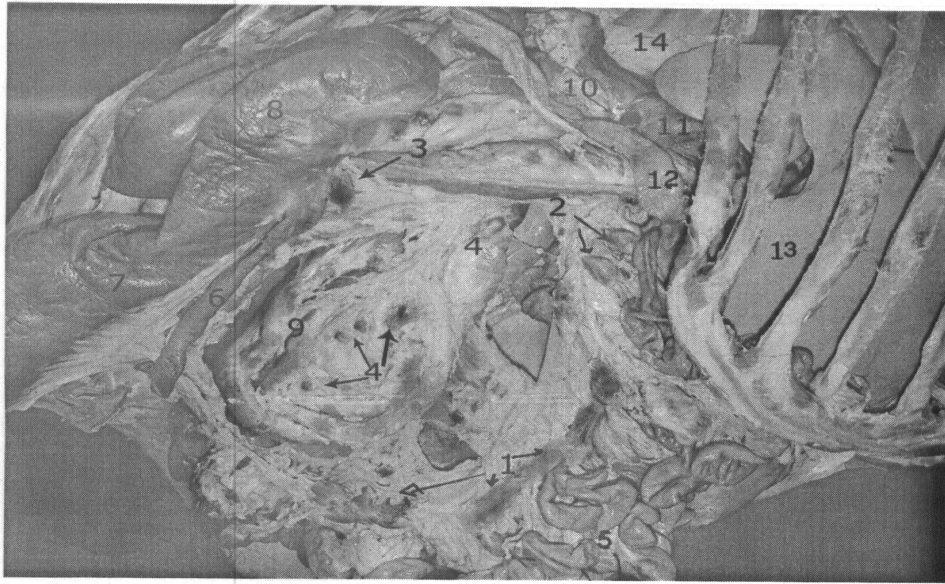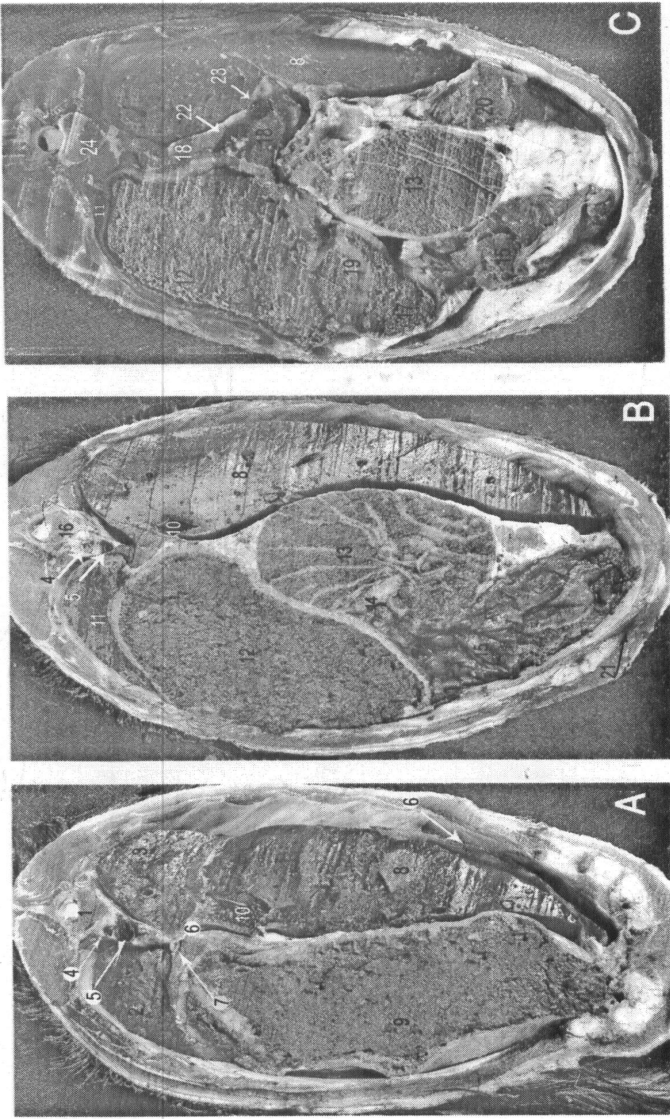


Fig. (36): Right lateral view of abdomen explained the cranial mesenteric lymph center.

1. Elongated jejunal lymph nodes.
2. Compact jejunal lymph nodes.
3. Cecal lymph nodes.
4. Colic lymph nodes.
5. Jejunum.
6. Ileum.
7. Cecum.
8. Proximal loop of ascending colon.
9. Spiral loop of ascending colon.
10. Pancreaticoduodenal lymph node.
11. Pancreas.
12. Duodenum.
13. Liver.
14. Right kidney.

Fig. (37): Cross sectional anatomy of the cranial abdomen of the goat showed stomach compartment, liver, spleen and pancreas.

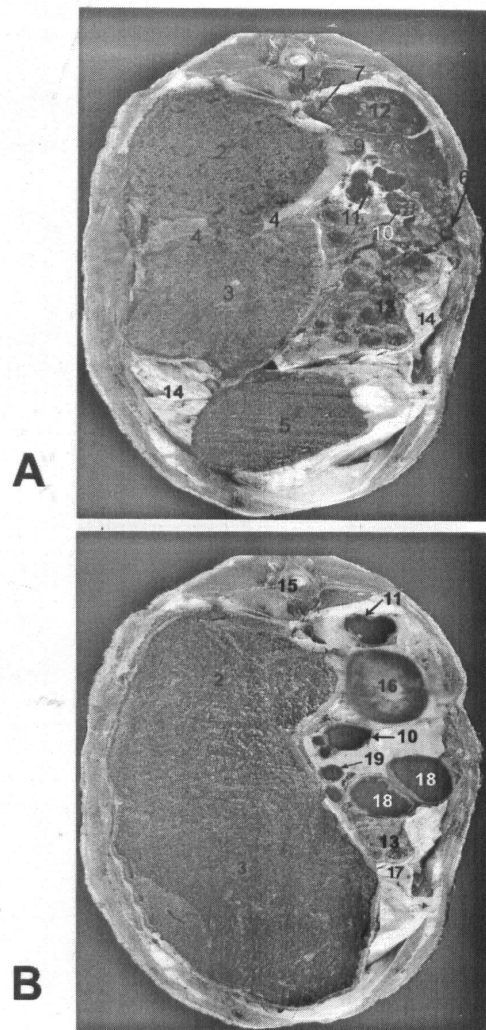
1. 7th thoracic vertebra.
2. Left caudal lobe of the lung.
3. Right caudal lobe of the lung.
4. Left vena azygos.
5. Aorta.
6. Diaphragm.
7. Esophagus.
8. Liver.
9. Reticulum filled with ingesta.
10. Caudal vena cava.
11. Spleen.
12. Dorsal ruminal sac.
13. Omasum.
14. Omasoabomasal opening.
15. Abomasum.
16. 10th thoracic vertebra.
17. Ventral ruminal sac.
18. Pancreas.
19. Cranial transverse pillar.
20. Pyloric part of abomasum.
21. Cranial epigastric artery.
22. Portal vein.
23. Hepatic artery.
24. 11th thoracic vertebra.



Cross sectional anatomy of the goat cranial abdomen showing stomach compartment, liver, spleen and pancreas

Fig. (38): Cross sectional anatomy of goat middle abdomen.

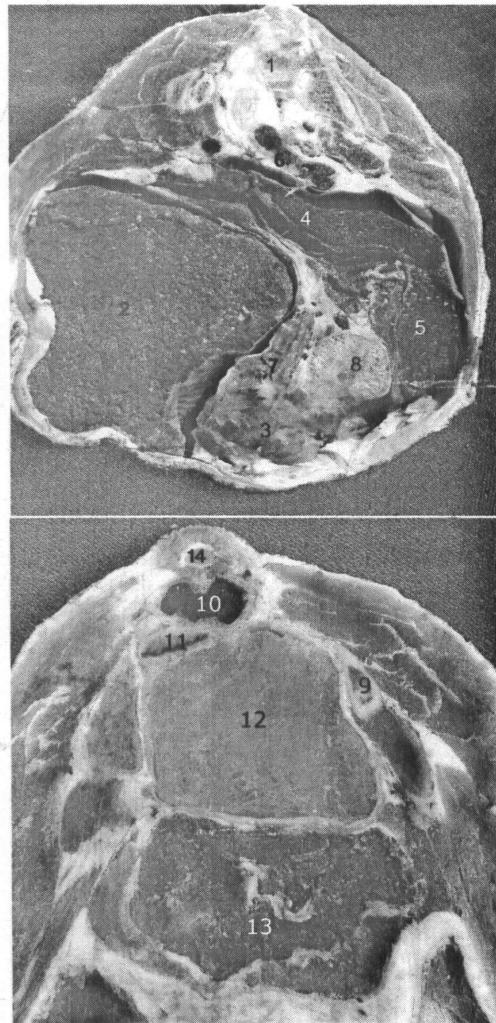
1. 1st lumbar vertebra.
2. Dorsal ruminal sac.
3. Ventral ruminal sac.
4. Right and left longitudinal pillar.
5. Abomasum.
6. Duodenum.
7. Caudal vena cava.
8. Caudate process of the liver.
9. Pancreas.
10. Distal loop of ascending colon.
11. Descending colon.
12. Right kidney.
13. Intestinal mass (jejunum).
14. Superficial layer of the greater omentum.
15. 3rd lumbar vertebra.
16. Left kidney.
17. Deep layer of the greater omentum.
18. Proximal loop of ascending colon.
19. Spiral loop of ascending colon.



A
B
Cross sectional anatomy of goat middle abdomen

Fig. (39): Cross sectional anatomy of the goat caudal abdomen.

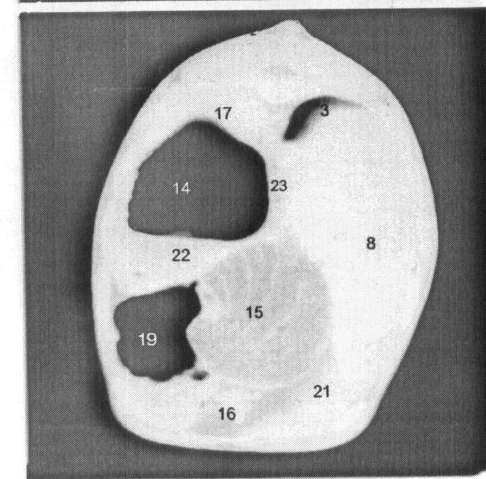
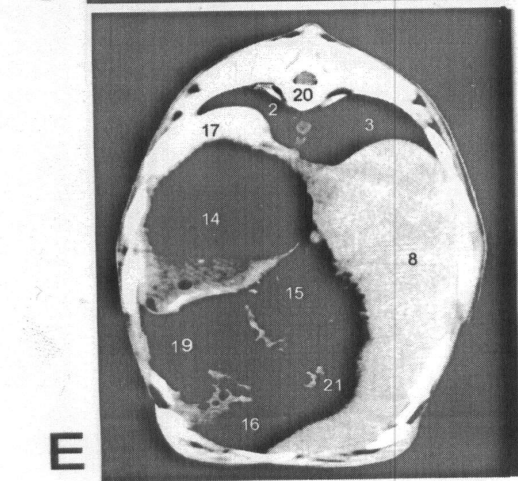
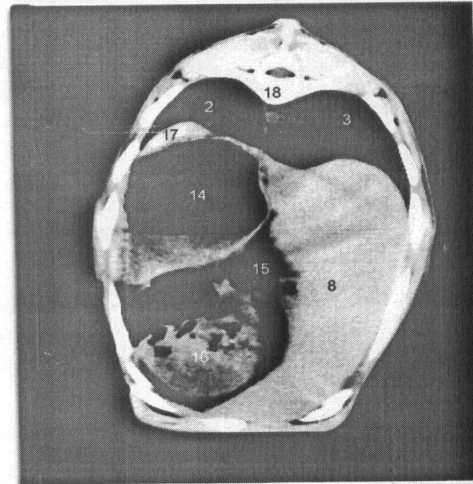
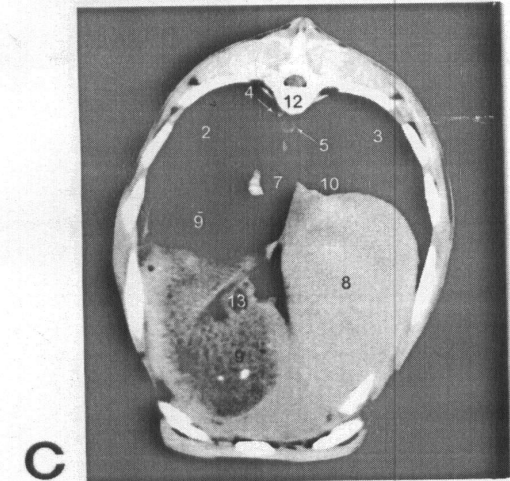
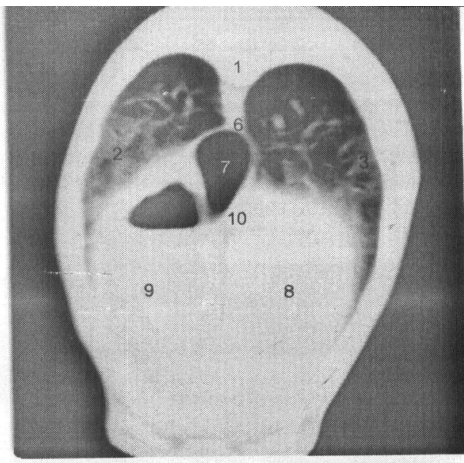
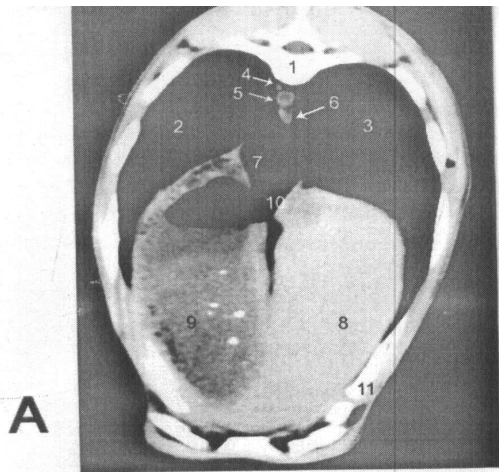
1. Cranial part of 6th lumbar vertebra.
2. Ventral ruminal sac.
3. Intestine.
4. Proximal loop of ascending colon.
5. Cecum.
6. Descending colon.
7. Spiral loop of ascending colon.
8. Jejunal lymph node.
9. Shaft of ileum.
10. Rectum.
11. Uterine body.
12. Urinary bladder.
13. Intestine.
14. 2nd sacral vertebra.



Cross sectional anatomy of the goat caudal abdomen

Fig. (40): Axial-images of the computed tomography of the goat, cranial abdomen, showing the stomach compartment, liver, spleen and pancreas (B & F) lung windows.

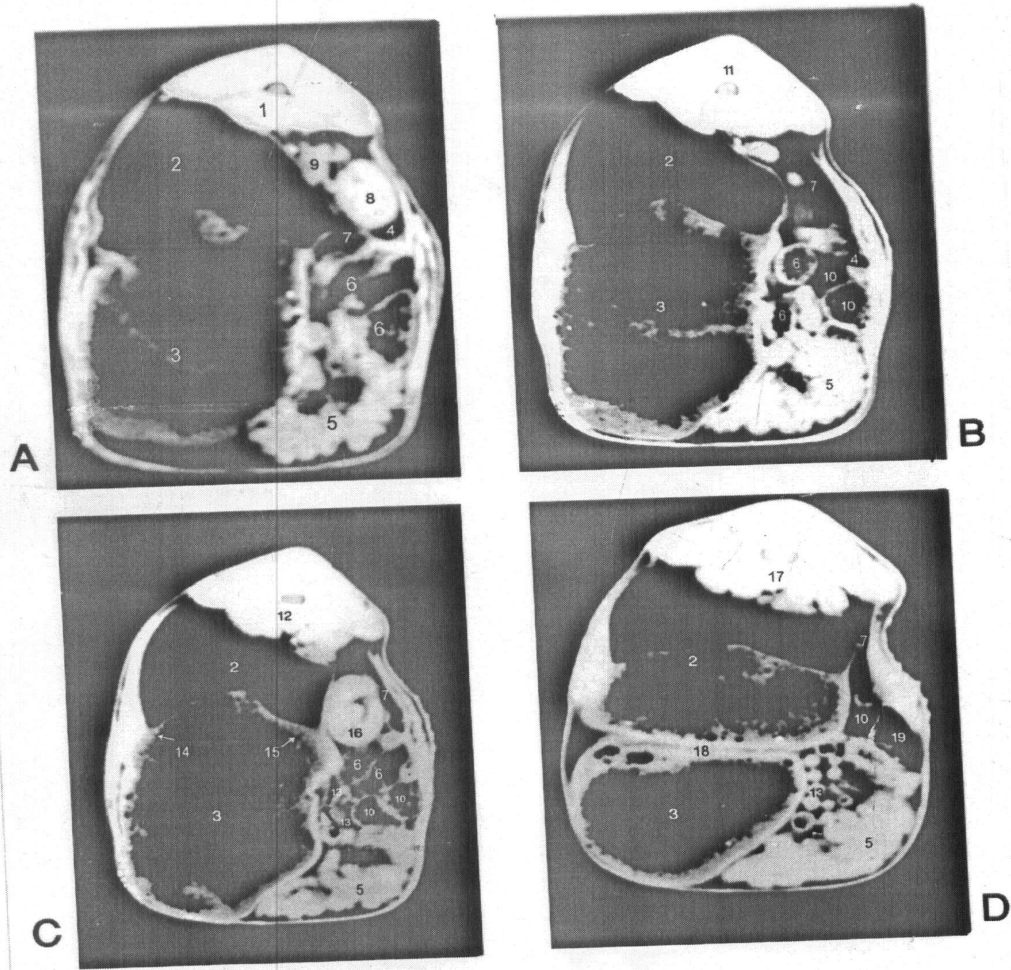
1. 7th thoracic vertebra.
2. Left caudal lobe of the lung.
3. Right caudal lobe of the lung.
4. Left vena azygos.
5. Aorta.
6. Diaphragm.
7. Esophagus.
8. Liver.
9. Reticulum. 9'. Reticulum filled with gases.
10. Caudal vena cava.
11. Right costal arch.
12. 8th thoracic vertebrae.
13. Reticular groove.
14. Dorsal ruminal sac.
15. Omasum.
16. Abomasum.
17. Spleen.
18. 10th thoracic vertebra.
19. Ventral ruminal sac.
20. 11th vertebra.
21. Pyloric part of abomasum.
22. Cranial transverse pillar.
23. Pancreas.



C.T-images of the cranial abdomen

Fig. (41): Axial images of the computed tomography of the goat middle abdomen.

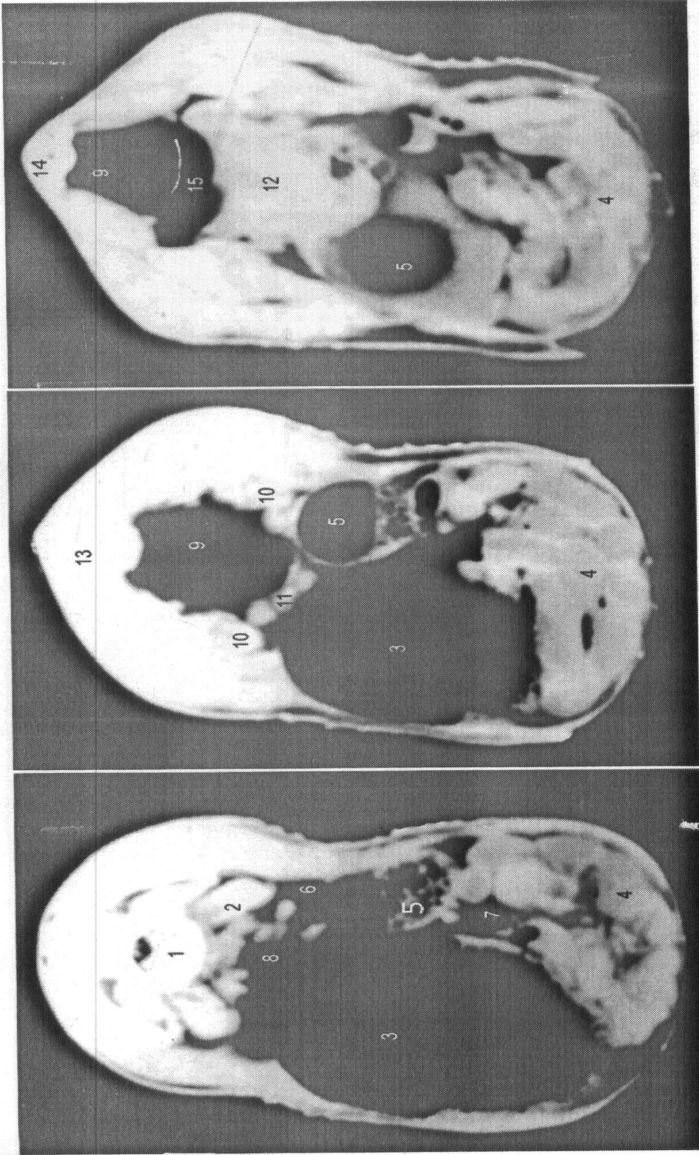
1. 1st lumbar vertebra.
2. Dorsal ruminal sac.
3. Ventral ruminal sac.
4. Duodenum.
5. Small intestine (jejunum).
6. Distal loop of the ascending colon.
7. Descending colon.
8. Right kidney.
9. Pancreas.
10. Proximal loop of the ascending colon.
11. 2nd lumbar vertebra.
12. 3rd lumbar vertebra.
13. Spiral loop of the ascending colon.
14. Left longitudinal pillar.
15. Right longitudinal pillar.
16. Left kidney.
17. 4th lumbar vertebra.
18. Caudal transverse pillar.
19. Cecum.



C.T- images of the middle abdomen

Fig. (42): Axial images of the computed tomography of the goat caudal abdomen.

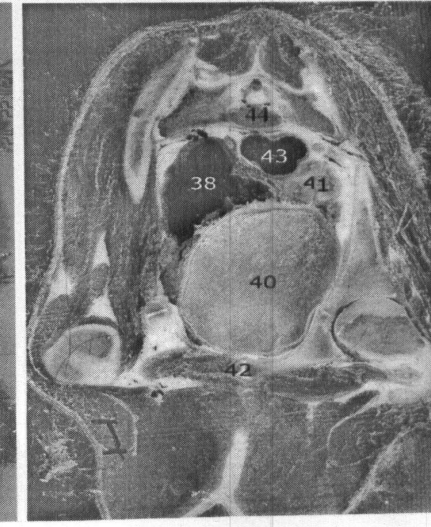
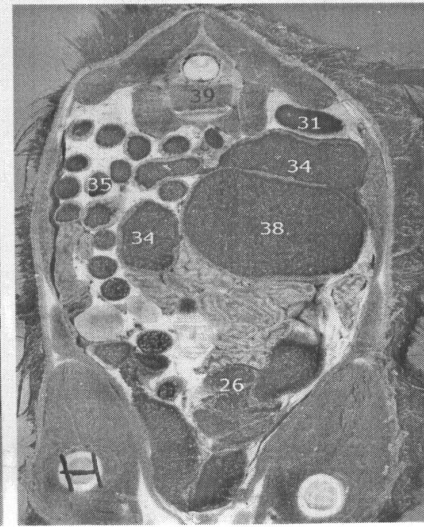
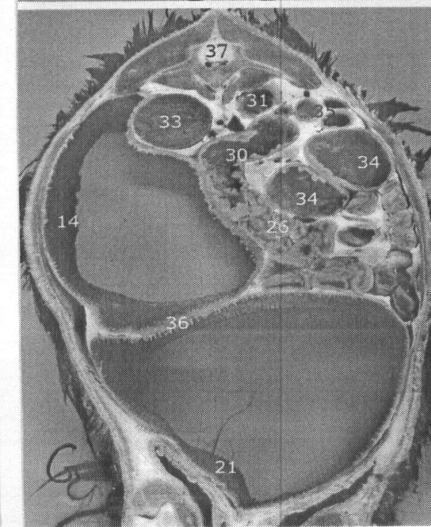
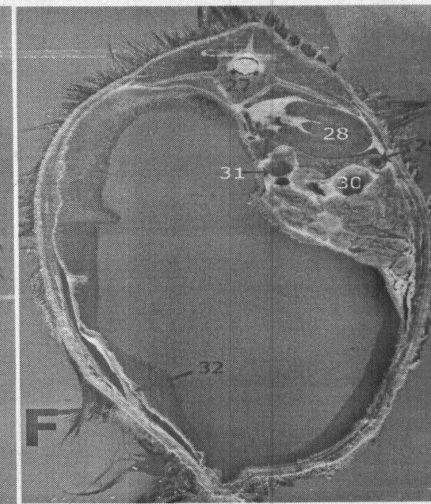
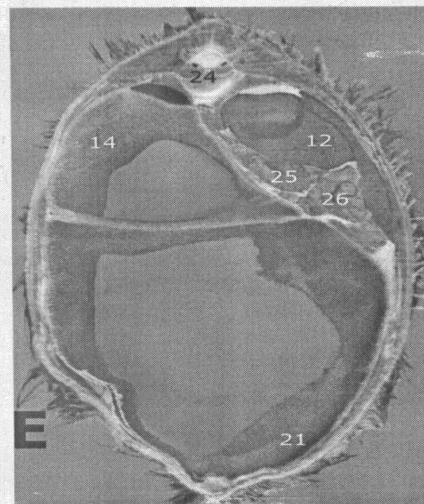
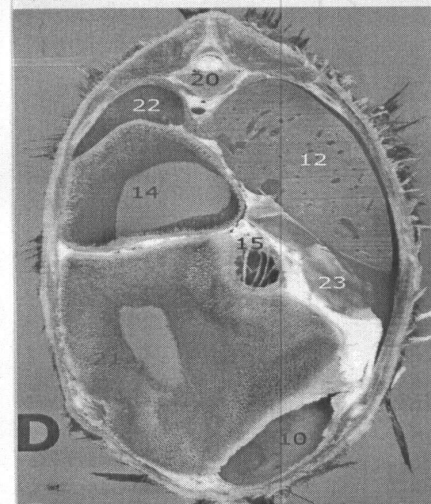
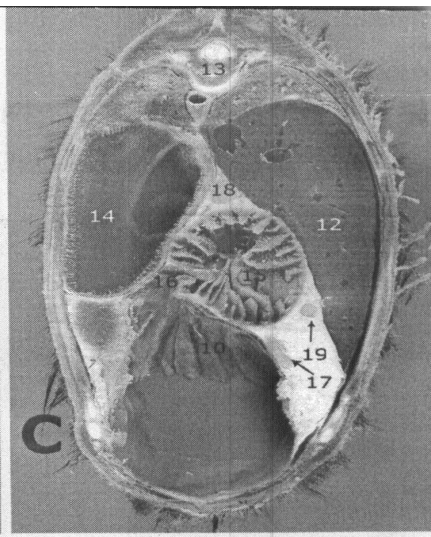
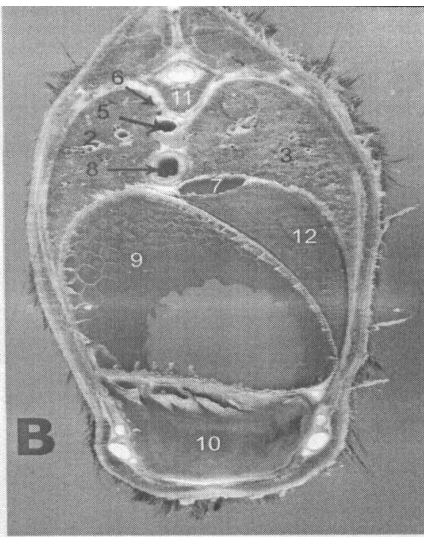
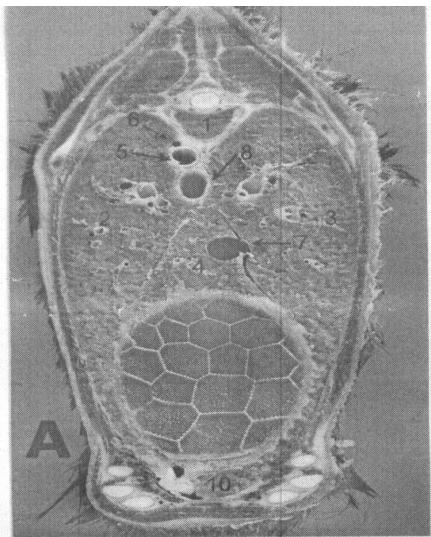
1. Cranial part of 6th lumbar vertebra.
2. Sublumbar muscle.
3. Ventral ruminal sac.
4. Small intestine.
5. Cecum.
6. Proximal loop of ascending colon.
7. Spiral loop of ascending colon.
8. Descending colon.
9. Rectum.
10. Ovary.
11. Uterine horn.
12. Urinary bladder.
13. Between 6th lumbar vertebra & sacrum
14. 2nd sacral vertebra.
15. Uterine body.



C.T images of the caudal abdomen

Fig. (43): Cross sectional anatomy of three months abdomen of immature goat.

1. 7th thoracic vertebra.
2. Left caudal lobe of the lung.
3. Right caudal lobe of the lung.
4. Accessory lobe caudal lobe of the lung.
5. Aorta.
6. Left vena azygos.
7. Caudal vena cava.
8. Esophagus.
9. Reticulum.
10. Abomasum.
11. 8th thoracic vertebrae.
12. Liver.
13. 9th thoracic vertebrae.
14. Dorsal ruminal sac.
15. Omasum.
16. Omasoabomasal opening.
17. Dorsal abomasal lymph nodes.
18. Omasal lymph nodes.
19. Hepatic lymph nodes.
20. 11^h thoracic vertebrae.
21. Ventral ruminal sac.
22. Spleen.
23. Gall bladder.
24. 12th thoracic vertebrae.
25. Pancreas.
26. small intestine
27. 1st lumbar vertebra.
28. Right kidney.
29. Duodenum.
30. Distal loop of ascending colon.
31. descending colon
32. Superficial layer of greater omentum.
33. Left kidney.
34. Proximal loop of ascending colon.
35. Spiral loop of ascending colon.
36. Caudal transverse pillar.
37. 3rd lumbar vertebra.
38. Cecum.
39. 5th lumbar vertebra.
40. Urinary bladder.
41. Uterine horn.
42. Pubis.
43. rectum
44. 2nd sacral vertebra



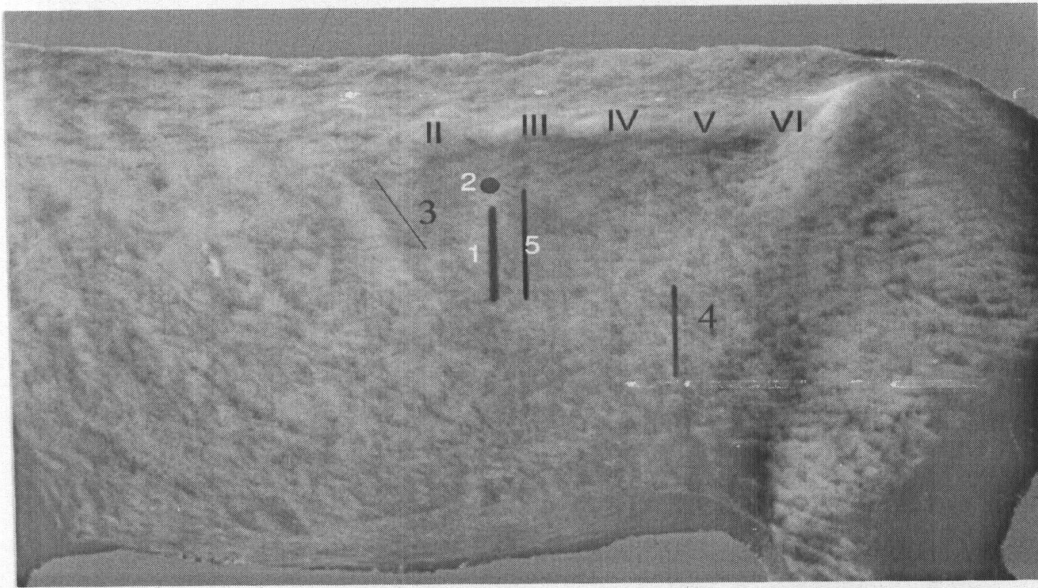


Fig. (44): left Lateral view of the abdomen of goat, explained the sites of the surgical approach of abdomen.

1. site of rumenotomy
 2. site of Rumenostomy
 3. site of surgical approach to spleen
 4. site of surgical approach to gravid uterus
 5. site of surgical approach to left kidney
- II TO VI** Number of lumbar transverse processes


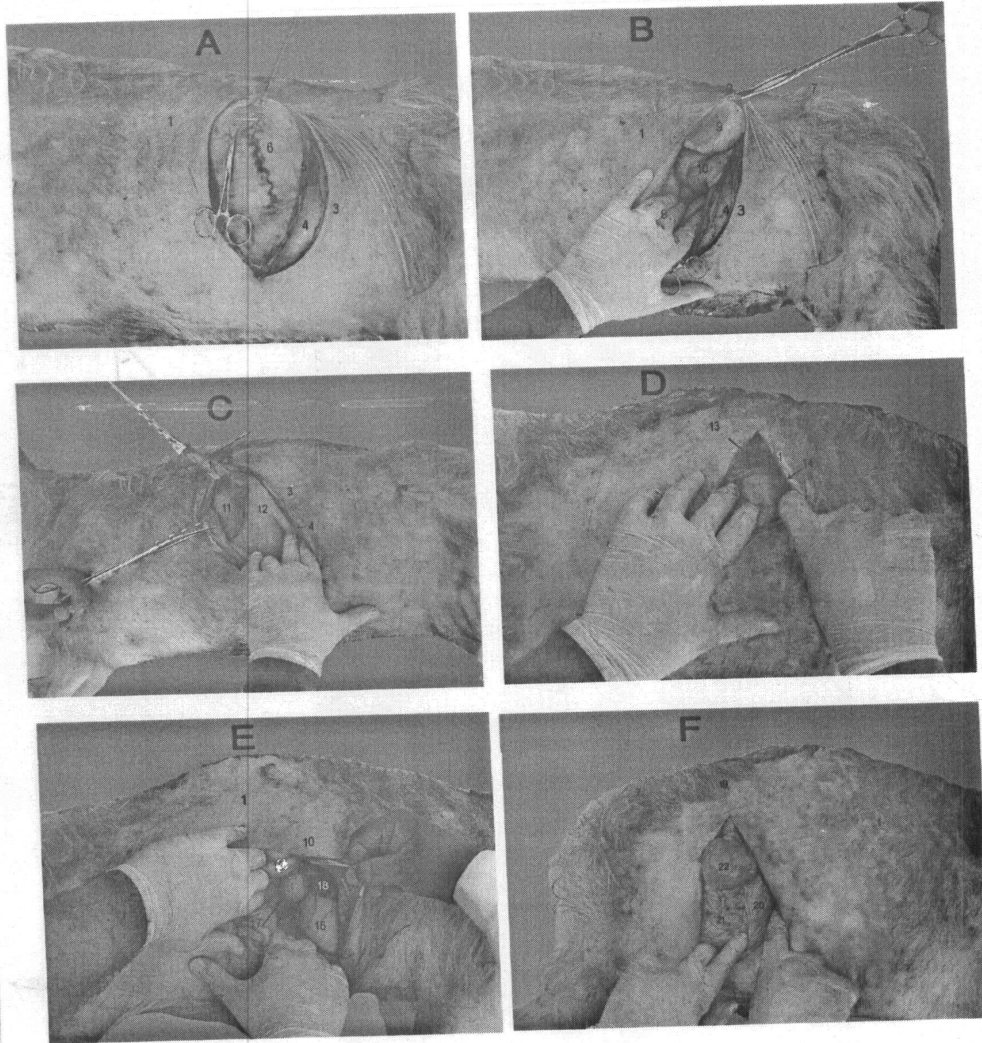


Fig. (45): right Lateral view of the abdomen of goat, explained the sites of the surgical approach of abdomen.

1. Site of surgical approach to right kidney.
 2. Site of surgical approach to liver.
 3. Site of surgical approach to gall bladder.
 4. Site of surgical approach to cecum.
 5. Site of surgical approach to abomasum
- I TO IV Number of lumbar transverse processes

Fig. (46): The surgical approach to the rumen (A) kidneys (B & D) spleen (C) gall bladder (E) and intestine (F).

1. Last rib.
2. 3rd lumbar transverse process.
3. Skin.
4. External abdominal oblique muscle.
5. Internal abdominal oblique and transverse abdominal muscles .
6. Dorsal ruminal sac.
7. tuber coxae:
8. Hand pushed the rumen:
9. Left kidney:
10. Spiral loop of ascending colon:
11. Spleen:
12. Ruminal atrium:
13. Right kidney:
14. Caudate process of the liver:
15. 10th rib.
16. Abomasum.
17. Gall bladder.
18. Quadrate lobe.
19. 4th lumbar vertebra.
20. Greater omentum.
21. Cecum.
22. Jejunum.



**surgical approach to rumen (A) kidneys (B,D)
spleen (C) gall bladder E and intestine (F)**

Discussion

I. The abdomen:

Our results denoted that the shape of the abdomen in adult goat was bulged laterally and abdominal floor was curved and the abdomen was bilaterally symmetrical excepted at the advanced pregnancy, while in the immature goat the abdomen was compressed laterally and shallower. These finding were in agreement with that obtained by **Dyce et al. (2002)** in ruminant.

Our study revealed that the abdomen divided into three large regions, cranial, middle and caudal abdominal regions by two transverse imaginary planes, the first at the caudal border of the costal arch and second at the tuber coxae, and by two sagittal planes passed through the middle of the inguinal ligament, the abdomen divided into nine regions. These result were similar that mentioned by **Getty (1975)** in domestic animals.

In present work the paralumbar fossa was triangular depression in the upper part of the flank it was bounded by 2nd to 6th lumbar transverse processes, cranially by the last rib and caudoventrally by the tension ridge created by the weight of abdominal viscera on internal abdominal muscle. These results were similar to that mentioned by **Garrett (1988)** in the goat, and **Small Wood (1992)** in ruminants excepted that the dorsal boundaries extended from 2nd to 5th lumbar transverse processes while in our work form 2nd to 6th lumbar transverse processes due to the tip of the 6th transverse lumbar process was curved cranially and cough palpated cranial to tuber coxae by 1-2 cm. The scar of umbilicus presented at the level between 1st and 2nd lumbar vertebrae, while **May (1977)** in sheep mentioned that the scar of umbilicus lied at level of 3rd lumbar vertebra.

II. Abdominal cavity:

In present investigation, the abdominal cavity was bounded dorsally by six lumbar vertebrae in most cases and in two cases were seven lumbar vertebrae and the associated muscle. The lateral and ventral walls were formed by the abdominal muscles, cranially by diaphragm and caudally by linea terminalis. This result is similar to that mentioned by **El-Hagri (1967)** in domestic animals and **Dyce et al. (2002)** in ruminants.

A. Abdominal wall

A.1-The layers of ventrolateral abdominal wall.

1- Skin

In our work the skin of goat was thinner in upper part of the flank than the ventral part however **Dyce et al. (2002)** in dog and horse, when the skin thicker over the flank but thin ventrally especially on the cleft between the abdomen and thigh.

2. Superficial abdominal fascia:

It was loose and cover the lateral and ventral abdominal wall dorsally, it continued to other side without any bony attachment and fused in part with thoracolumbar fascia, cranially continuous with fascia of shoulder and arm but caudally with that of gluteal region and contained cutaneous muscle, subiliac lymph node. the similar findings were mentioned by **Getty (1975)** in ruminants ,while **Nickel et al. (1986)** in ruminant mentioned

that there were detach slips form fascia which find insertions on free ends of thoracic and lumbar spinous processes.

3. Cutaneous trunci muscle:

In present work, the cutaneous trunci muscle was rectangular sheet of muscle fiber extending along the lateral abdominal and thoracic wall. It originated from the superficial layer of the thoracolumbar fascia. The muscle fiber continued cranially with cutaneous omobranchialis muscle, fleshy portion of muscle was separated dorsally by a wide increasing space as traced caudally, ventrally it communicated with its fellow of opposite side along lateral border of preputial muscle, similar observation was reported by **Abd Elmoien (1995)** in goat, while **Getty (1975)** in ruminant mentioned another origin from interbrachial fascia on the medial surface of the arm moreover **Smuts and Bezuidenhout (1987)** in camel didn't observe the cutaneous trunci muscle.

4. Cranial preputial muscle:

It was a thin muscular band arising from the fascia caudal to xiphoid cartilage and inserted in the dorsolateral aspect of the prepuce behind the preputial orifice, these findings similar to mentioned by **May (1977)** in sheep and **Getty (1975)** ruminant but stated that some fibers passed to caudolateral surface of the prepuce.

5. Caudal preputial muscle:

It was detached from the cranial end of the tuber ischii in common with fiber of the semimembranosus muscle by 2 to 3 narrow tendons reinforced by another fascicles originated from abdominal tunic on the level of the superficial inguinal ring and terminated at the dorsolateral aspect of the prepuce. Similar observation was reported by **Abd Elmoien (1995)** in goat, while **May (1977)** in sheep observed that, it arose cutaneously cranial to the neck of the scrotum.

6. Supramammary muscle:

It was two muscular bands arose from abdominal tunic caudal to the xiphoid cartilage by 6-8 cm; it terminated by along common tendon on the cranial aspect of the base of the udder. These results showed little difference with that of the she-camel as mentioned by **Smuts et al. (1987)** that it terminates on the base of the udder just above the caudal teat.

7. The flava abdominal tunic:

In the present work, it was yellow elastic sheet covering the distal half of the lateral thoracic and abdominal walls from the 6th rib cranially to the tuber coxae caudally, it was much obvious and could be peeled out at the cranial half of the fleshy portion of the external abdominal oblique muscle and on ventral abdominal wall especially caudal to umbilicus. It was few fiber at the caudal part of the external abdominal oblique muscle while thick at the ventral abdominal wall similar observation was reported by **May (1977)** in sheep and **Garrett (1988)** in the goat.

8. External abdominal oblique muscle:

The muscle arose somewhat caudal to 6th rib up to the last rib similar finding mentioned by **Getty (1975)** in ruminant and **May (1979)** in sheep and **Smuts et al. (1987)** in camel in addition to thoracolumbar fascia in sheep and camel.

The muscle fiber of the cranial portion ran caudoventrally toward the linea alba while the caudal part came from the last two ribs had horizontal direction and extended to tuber coxae. This observation similar to finding by **Getty (1975)** in goat, while in ox the muscular portion extended only for 4th lumbar vertebra. The insertion of the external abdominal muscle was by an aponeurosis to the linea alba, pelvic symphysis and tuber coxae. These result similar to obtained by **Getty (1975)** in goat and **May (1977)** in sheep. The muscle terminated by broad glistening aponeurosis which in both epigastric and mesogastric regions the aponeurosis interwoven and over crossed by those of internal abdominal oblique muscle till linea alba while in the hypogastric region aponeurosis continued superficial to aponeurosis of the internal oblique muscle. These results observed also by **Abd Elmoien (1995)** in goat and **Rizk (1980)** in kangaroo while **Getty (1975)** in ruminant and **May (1977)** in sheep mentioned the aponeurosis of external abdominal oblique muscle was superficially to aponeurosis of the internal abdominal oblique one.

In our work the inguinal ligament extended from the tuber coxae to cranial half of ventral aspect of the pelvic symphysis. These result were similar to that mentioned by **Abd Elmoien (1995)** in goat, while **May (1977)** in the sheep mentioned the prepubic tendon instead of pelvic symphysis.

9. Internal abdominal oblique muscle:

In present work, this muscle was represented by a triangular fleshy portion originated from the tuber coxae, upper third of the inguinal ligament and from the thoracolumbar fascia by very thin aponeurosis on a level of the last lumbar vertebra and their muscle fibers fanned out cranioventrally toward the linea alba similar observation was reported by **Abd Elmoien (1995)** in goat and **May (1977)** in sheep while **Dyce et al. (2002)** in ruminant reported that the different origin where arose from transverse process of the lumbar vertebrae and tuber coxae and lateral crus of the aponeurosis of external abdominal muscle.

The most dorsal fascicle terminated into the caudal border of the last rib, similar to the observation of **Getty (1975)** in ruminants, while to the last three or four ribs as mentioned by **May (1977)** in sheep. The muscle fibers continued cranioventrally by a broad thin, glistening aponeurosis, which terminated at linea alba and prepubic tendon. The aponeurosis of the internal abdominal muscle before decussated and under costochondral junction of 12th rib by 5-6 cm gave an narrow band derived from this aponeurosis and run over the inner surface of the rectus abdominal muscle and sharing in formation of the inner lamina of the rectus sheath, the similar result observed by **Getty (1975)** in ruminant and **Abd Elmoien (1995)** in goat.

10. Straight abdominal muscle :(M. Rectus abdominis)

In our work, the rectus abdominal muscle arose by a long thin tendon from the lateral border of the sternum and costal cartilages of 4th to 8th ribs. Similar observation obtained by **Getty (1975)** in ruminant, while in **May (1977)** in sheep it arose from lateral border of sternum and from 3rd to 8th costal cartilages. The rectus abdominal muscle consisted of seven segments and six transverse tendinous intersections similar results recorded by **Abd Elmoien (1995)** in goat. While **May (1977)** in sheep it consisted of four or five tendinous intersections.

The prepubic tendon was narrow triangular and attached to the ventral surface of the caudal half of the pelvic symphysis in contrast to what was given by **Raghavan and Kachroo (1964)** in ox and **Getty (1975)** in ruminants where they gave an attachment to the pectin of pubis and symphyseal ligament.

11. Transverse abdominal muscle:

In present work, the transverse abdominal muscle is divided into the costal and lumbar parts, the former one originated from the medial aspect of the costal arch and last four ribs and the lumbar part originated by a thin aponeurosis from the first five lumbar transverse processes. These results are in agreement with result obtained by **Abd Elmoien (1995)** in goat and **May (1977)** in sheep, while **Beaver (1980)** in ruminant mentioned another origin in the lumbar part from the lumbodorsal fascia.

The muscle fibers of the transverse abdominal muscle ran distally toward the linea alba. The muscle is inserted by aponeurosis into the xiphoid cartilage and linea alba, The caudal portion of the aponeurosis of the transverse abdominal muscle proceeded distally for 1 to 2 cm where it splitted into a superficial and deep layers. This arrangement gave a strong support for the transverse aponeurosis against heavy weight of viscera and in pregnancy cases. These result similar to obtained by **Abd Elmoien (1995)** in goat and **Rizk (1980)** in kangaroo.

Inguinal canal:

In our investigation, the caudolateral wall of the inguinal canal was formed by the inguinal ligament and lateral crus of the aponeurosis of the external abdominal oblique muscle. While craniomedially it was formed by the caudal portion of the internal abdominal oblique muscle, these were observed by **Abd Elmoien (1995)** in goat and **May (1977)** in sheep added that the caudomedial wall is formed by the prepubic tendon and transverse fascia, while **Evans and Delahunta (1988)** in dog denoted that the caudal fiber of transverse abdominal muscle and lateral portion of the last segment of the rectus abdominal muscle sharing in formation the caudal wall of the inguinal canal.

The superficial inguinal ring was represent by a slit between both crura of the external abdominal oblique aponeurosis, on the other hand, **Sisson (1975)** in the horse, revealed that the medial boundary of the superficial inguinal ring was formed by the lateral concave border of the prepubic tendon, while **Yadm and Erasha (1990)** in the rabbit mentioned it was situated between the lateral and intermediate aponeurotic sheets of the external abdominal oblique muscle.

The deep inguinal ring was bounded by the caudal border of the fleshy portion of the internal abdominal oblique muscle and ventral portion of inguinal ligament, similar statement was given by **Getty (1975)** in ruminant while **Yadm and Erasha (1990)** in rabbit and cat, observed that it was found between the internal abdominal oblique muscle and the prepubic tendon.

In male, the vaginal tunic of the testis and the spermatic cord traversed the canal craniomedially and cremaster muscle traversed it caudolaterally in addition to the external pudendal vessels and the genital nerve, such an arrangement was observed also by **Getty (1975)** in ruminant and **May (1977)** in sheep.

A, 2. Arterial supply of the abdominal walls

1. Cranial epigastric artery:

In our work, the cranial epigastric artery was the caudal continuation of the internal thoracic artery after giving the musculophrenic branch at the caudal border of the 7th costal cartilage, it gave the cranial superficial epigastric artery and continued through the substance of the rectus abdominal muscle in agreement with statement of both **Ghoshal (1975)** and **Schummer et al. (1981)** in ruminants. It gave 5 to 7 pairs of medial and lateral branches which were segmentally arranged and it anastomosed with caudal epigastric artery, similar observation was given by **Hifny et al. (1984)** in mule, while **Badawi et al. (1983)** in camel, mentioned that there was not anastomosis existed between the cranial and caudal epigastric arteries.

2. Cranial superficial epigastric artery:

In our work, it arose from the lateral aspect of the cranial epigastric artery which supplied mainly the cutaneous trunci muscle, supramammary, cranial preputial muscle and anastomosed with caudal one at the craniolateral to preputial orifice, these result is similar to obtained by **Abd Elmoien (1995)** in goat and **Schummer et al. (1981)** in ruminants while **Hifny et al. (1982)** in camel considered it as a branch of the internal thoracic artery:

3. Musculophrenic artery:

It started at the level of the caudal border of 7th costal cartilage, the same result recorded by **Attia (1980 and 1987)** in camel and buffalo and **Yossef (1987)** in goat while at 8th in sheep as mentioned by **May (1977)**.

4. The dorsal intercostal arteries:

They originated from thoracic aorta; they formed the main blood supply of the costal part of the external abdominal oblique muscle and vascularized the cutaneous trunci muscle by two rows of cutaneous branches and the last three dorsal intercostal arteries terminated in the transverse abdominal muscle. Such result obtained by **Abd Elmoien (1995)** in goat, while **Raghavan and Kachroo (1964)** in ox mentioned that they form the 8th or 9th to 13th continued in the abdominal muscle.

5. Dorsal costoabdominal artery:

It originated from abdominal aorta, passed caudal to last rib and terminated into transverse abdominal muscle and rectus abdominal muscle. Similar result denoted by **Hifny et al. (1984)** in camel and **Abd-Elmoien (1995)** in goat

6. Caudal superficial epigastric artery:

It constituted the cranial division of the external pudendal artery in male and in female considered as direct continuation of the cranial mammary artery and anastomosed with the cranial superficial epigastric artery. These results are in agreement with the statement of **Abd Elmoien (1995)** in the goat, while **Smuts and Bezuidenhout (1987)** in camel mentioned that it was given from the pudendoepigastric trunk.

7. Caudal epigastric artery:

It arose from the pudendoepigastric trunk and gave 2 – 3 branches to last segment rectus abdominal muscle, similar results obtained by **Ghoshal (1975)** in ruminant.

8. Deep circumflex iliac artery:

It arose from the external iliac artery and divided into cranial and caudal branches, the former furnished the transverse abdominal, internal and external abdominal oblique muscles, while the caudal branch passed caudoventrally and pierce the abdominal wall, these results are in agreement with obtained by **Ghoshal (1975)** in ruminant and **Abd Elmoien (1995)** in goat, while **Saber (1979)** and **Badawi et al. (1983)** in the camel added that the artery was represented by two separated vessels; a cranial and a caudal originating from the external iliac artery. Moreover **Hifny et al. (1981)** in the mule and **Schummer et al. (1981)** in ox recorded that the deep circumflex artery originated from the external iliac artery or from the angle between it and aorta or from the external iliac artery.

A.3. Venous drainage of the abdominal wall**1. Cranial epigastric vein:**

It was one of two terminal branches of internal thoracic vein at beyond the 7th interchondral space, then passed through the rectus abdominal muscle and anastomosed with the caudal one caudal to umbilicus these result recorded by **Abd-Elmoien (1995)** in goat. Moreover **Schummer et al. (1981)** stated that it originated at 7th or 8th rib in small ruminant.

2. Cranial superficial epigastric vein:

It was the continuation of the cranial epigastric vein as it pierced the rectus abdominal muscle and external lamina of the rectus sheath to be subcutaneously similar results obtained by **Abd-Elmoien (1995)** in goat.

3. Musculophrenic vein:

It originated from the internal thoracic vein at 7th interchondral space and gave 7th to 9th ventral intercostal rami, these result in agreement with obtained by **Abd Elmoien (1995)** in goat while it detached from 7th or 8th interchondral spaces as mentioned by **Schummer et al. (1981)** in small ruminant.

4. Dorsal intercostal veins:

7th to last dorsal intercostal veins drained the external abdominal oblique muscle and cutaneous trunci muscle and gave cutaneous branches like satellite artery these results are similar to that given by **Abd Elmoien (1995)** in goat.

5. Dorsal costoabdominal vein:

It detached from the left vena azygos by a common trunk with the last intercostal vein on the level of the last thoracic vertebra. These result are in agreement with **Ghoshal et al. (1981)** in small ruminant, while **Smuts and Bezuidenhout (1987)** in camel mentioned that it detached from the right vena azygos.

6. Caudal superficial epigastric vein:

It was a direct continuation of the external pudendal vein after emerged from the superficial inguinal ring in male, while in female; it considered the direct continuation of the cranial mammary vein in front of the cranial end of the udder, similar results obtained by **Abd Elmoien (1995)** in goat.

7. Caudal epigastric vein:

It was detached from the pudendoepigastric vein in agreement with **Ghoshal et al. (1981)** in ruminant while **Yadam (1990)** in the she donkey mentioned it arose from external iliac vein in two cases and from deep femoral vein in most cases.

8. Deep circumflex iliac vein:

It arose from the common iliac vein and divided into the cranial and caudal branches, these results are in agreement with **Abd Elmoien (1995)** in goat, while **Retting (1969)** in ox observed that it was occasionally paired vessels on right side and arose from caudal vena cava and left from the common iliac vein.

A,3.The main nerve supply of the lateral abdominal wall**1. Costoabdominal nerve:**

In present work, it was the ventral division of 13th thoracic nerve, passed under the cranial point of 1st lumbar transverse process then passed caudally 0.5 to 1 cm behind to satellite vessels and divided into lateral and medial rami. Similar observation is mentioned by both **Garrett (1988)** and **Abd Elmoien (1995)** in the goat, while it derived from 12th or 13th thoracic spinal nerves as mentioned by **Ghoshal (1975)** in sheep.

2. The iliohypogastric nerve:

It was the ventral branch of the 1st lumbar nerve in most cases, but in two cases as the ventral branch of the 1st and 2nd lumbar nerve. It ran caudoventrally and passed under the tip of the 2nd lumbar transverse process and divided into medial and lateral branches. Similar observation obtained by **Garrett (1988)** in goat and **May (1977)** in sheep while **Abd Elmoien (1995)** in goat **Smuts et al. (1987)** in camel in the most cases there are two iliohypogastric, cranial and caudal nerves, the cranial iliohypogastric, is the ventral division of the 1st lumbar nerve, while the caudal one was the ventral division of 2nd lumbar nerve.

3. The ilioinguinal nerve:

It was the ventral branch of 2nd lumbar nerve, but in two cases considered as the ventral of the 3rd lumbar nerve. It passed caudoventrally under the middle the transverse process of the 3rd lumbar vertebrae, it passed under the cranial point of the transverse process of the 4th lumbar vertebra. Similar observation obtained by **Garrett (1988)** in goat and **Dyce et al. (2002)** in ruminant. While **Abd Elmoneim (1983)** in camel and **Abd Elmoien (1995)** in goat mentioned that the ilioinguinal nerve arose from the ventral branch of the third lumbar spinal nerve. This nerve is divided into cranial and caudal branches after leaving the spinal canal; the cranial branch gave the medial and lateral rami. These results are in agreement with **Raghavan and Kagchroo (1964)** in

ox and Abd Elmoien (1995) in goat and added that the ilioinguinal nerve had no relation to formation the genital ramus these result found in our work.

In our work to block the nerves that supply the paralumbar fossa we must block the ventral branches of T13, L1 and L2 by introduce needle with 2ml of anesthesia at the cranial tip of transverses processes L1, L2, L3 and L4, these observation recorded by Garrett (1988) in goat while Kumar (1988) in sheep restricted on first three lumbar transverse processes.

4. The genitofomral nerve:

It was the ventral branch 3rd lumbar nerve but in two cases considered as the ventral branch of the 4th lumbar nerve it passed under the 6th lumbar transverse process and take branch from ventral branch of 4th lumbar nerve to gave the genital branch, the same result obtained by Linzell (1959) in the goat.

B. Diaphragm:

In this respect, the diaphragm was appeared as a dome shaped musculotendinous plate; the abdominal surface was concave and covered by extension of transverse fascia and peritoneum. The midline slope of diaphragm extended from the ventral extremity 6th rib till the last thoracic vertebra same result obtained ELsafy (2005) in dog, while May (1977) in sheep the midline slope from the last thoracic vertebra to level the ventral end of 7th rib. The diaphragm consisted of a small tendinous central part surrounded by radiating muscles of the fleshy part which can divided into the lumbar part dorsally, the costal part laterally and the sternal part ventrally. The right crus of the lumbar part is larger than the left crus. The right and left crura were originated by a large common tendon which attached to ventral longitudinal ligament at the level of 2nd to 6th lumbar vertebrae; this finding was in a line with that recorded by Ahmad (1999) in buffalo.

The costal fleshy part of diaphragm in our study consisted of muscle fiber which radiated from the costal wall to the tendinous center by indistinct serration from 9th costochondral junction about distal one fourth of 10th rib and nearly to middle 12th rib till the ventral to proximal part of the last rib by 2 cm. these results differ little from Getty (1975) which denoted that the line of the origin of costal part began at the boundary of dorsal third of 12th rib, it coursed through the middle of 11th rib ,one third of 10th rib ventral one fourth of 9th rib and to costochondral junction 8th rib.

The sternal part of diaphragm was separated from costal part by thin bands and its fibers attached to abdominal surface of xiphoid cartilage and to 8th costal cartilage on each side. These result in line with Nickel et al. (1986) in ruminant and Ahmed (1999) in buffalo excepted there denoted that the sternal part unseparated from the bilateral costal portions.

III. Abdominal organs:

Rumen:

The rumen occupied most of the left portion of abdominal cavity, extended from part opposite 8th or 9th rib to the level of tuber coxae and dorsal ruminal sac was longer

than ventral one, these results were similar to that donated by **May (1977)** in sheep while from 7th rib till the pelvic inlet as mention by **Hifny et al. (1985)** in camel.

In present work the dorsal ruminal sac came in contact with the left paralumbar fossa and ventral ruminal sac was enclosed by greater omentum these results similar to mentioned by **Habel (1975)** and **Dyce et al. (2002)** in ruminant. The site of auscultation and palpation of the rumen and trocarization for relief of tympany presented under the 3rd lumbar transverse process. These results in line with **Garrett (1988)** in goat.

The rumen appeared completely in lateral and ventrolateral radiograph with contrast media after 1 hour from administration of barium sulfate, it extended from 8th rib cranially to the junction between the 6th lumbar vertebra and sacrum caudally and from vertebral column dorsally to abdominal floor ventrally. These results on line with **Cegarra and Lewis (1977)** in goat, while **Sharma et al. (1984)** in ovine, it began at level of 10th rib.

Reticulum:

It was piriform in the shape, lied almost entirely to the left of the median plane, it extended from the 6th rib or 6th intercostal space to the 8th rib or 8th intercostal space and extend ventrally till the abdominal floor in adult goats, is position similar to that recorded by **May (1977)** in sheep, **Dyce et al. (2002)** and **Habel (1975)** in ruminant ,while it extended from 7th to 10th rib in camel and did not reach the abdominal floor as mentioned by **Hifny et al. (1985)**.

The area of auscultation of the reticulum located at the ventral end of 6th and 7th intercostal space in adult goat also the site of percussion of the reticulum was detected at the left part of xiphoid region these result similar that denoted by **Delahunta and Habel (1986)** in ruminant.

The reticulum appeared in lateral abdominal radiographs with contrast media as piriform structure and located just behind diaphragm ,it extend from 6th to 8th intercostal space and ventrally it touched the abdominal floor in the left xiphoid region. These results similar to obtained by **Abu Zaid (1995)** in goat, while **Kanwar et al. (1983)** in the caprine it extended from 7th to 9th intercostal spaces.

Omasum:

in current work, the omasum was bean in shape lied in intrathoracic part of the abdominal cavity right to the median plane between liver on the right and rumen and reticulum on the left and abomasum ventrally, it extended from 7th to 9th intercostal spaces or 8th to 10th ribs and did not contact to abdominal wall. These results are similar to that recorded by **Dyce et al. (2002)** in sheep and goat while in ox extended from 8th to 11th ribs and contacted the abdominal wall while **May (1977)** in sheep mentioned that it extended from 9th to 10th rib. While from 7th for 10th ribs in camel as mentioned by **Hifny et al. (1985)**. In lateral radiograph with contrast media, the omasum was identified after 10 minutes of barium administration as bean structure extended from 8th to 10th ribs while in ventrodorsal view it appeared as oval shape organ extended between 8th or 9th to 12th interchondral spaces, similar result obtained **Abu Zaid (1995)** in goat.

Abomasum:

It extended from 8th to 12th intercostal spaces or 13th rib, the fundus of abomasum lied centrally in the xiphoid region, the body of abomasum extended on the abdominal floor then inclining to right and extend a little ventral to right costal arch and almost parallel with it and the pyloric part turned to the right caudal to omasum and bend up to lateral wall of abdominal cavity till ended at pylorus, these results in agreement with **May (1977)** in sheep and **Dyce et al. (2002)** in small ruminant.

In X-ray with contrast media, the abomasum appeared after 20 minutes in lateral radiograph; it appeared only the fundus which presented between the reticulum and ventral ruminal sac, while in the ventrodorsal radiograph the abomasum located mainly in the right side of abdominal cavity and similar results observed by **Cegarra and Lewis (1977)** in goat.

Omenta:

In the present work, the greater omentum was consisted of two layers, superficial and deep layer. The superficial one arose from the left longitudinal groove of the rumen then passed ventrally to rumen then dorsally to attached with greater curvature of the abomasum, the caudal border of the cranial part of the duodenum and ventral border of the descending duodenum. While the deep layer attached the right longitudinal groove of the rumen. It passed ventrally in contact with visceral surface of the ventral sac of rumen then turned dorsally to unite with the superficial layer on the ventral of descending duodenum. Similar result are obtained by **Nickel et al. (1973)** in ruminant and **May (1977)** in sheep.

The lesser omentum, as observed in the present study. It consisted of the hepatogastric ligament was attached from esophageal notch till the cranial porta hepatis to the lesser curvature of abomasum and parietal surface of omasum and lesser curvature of reticulum, while hepatoduodenal ligament attached from porta hepatis to cranial part of the duodenum. These results were in a line with the findings of **Awad (2000)** in goat, **Habel (1975)**, **Anis (1977)** and **ElGaafary et al (1979)** in large ruminants, moreover **ElGaafary et al (1979)** in buffalo and **Badawi , Abd El-Moneim and Ibrahim (1984)** in camel added that the lesser omentum continued towards the caudate process as well as hepatorenal ligament.

Intestine:

In present study, the duodenum extended from the pylorus at the ventral fourth of 10th intercostal space to duodenojejunal flexure. The cranial part of duodenum passed dorsally to visceral surface of the liver and form S-shape flexure. The descending duodenum ran horizontal to the level of the 5th lumbar vertebra then to form its flexure. The ascending part passed cranially where become medioventrally to descending colon where attached them by duodenocolic ligament and dorsally to the distal loop of ascending colon then form S-shaped curve at the level of 1st lumbar vertebra, similar are results observed by **Habel (1975)** in ruminants and **May (1977)** in sheep with little difference, where the descending duodenum run caudal till the tuber coxae. In present work the descending duodenum and caudal flexure of the duodenum were only parts of the intestine were visible on opening the right flank.

The jejunum was the longest part of small intestine formed numerous close coils arranged in a festoon around the free border of mesentery, lied in the supraomental recess on right side of abdomen, and sometimes it presented out side the supraomental recess and shifted to left side behind the rumen. The ileum was shortest part of small intestine which opened in cecum and ascending colon by iliocecolic opening, these results are similar to obtained by **Habel (1975)** and **Dyce et al. (2002)** in ruminant.

In present work, the small intestine began to have contrast material after one to three hours after barium administration. In the lateral radiographs, it was not appear in the area covered by the rumen but only detected just behind it as convoluted radiolucent bands, similar results observed by **Cegarra and Lewis (1977)** and **Abu Zaid (1995)** in goat.

In present investigation the cecum located against the right flank separated from it by the greater omentum. It located in the dorsal caudal two thirds of the abdominal cavity. It extended from the level of the 3rd or 4th lumbar vertebra till pelvic inlet. Its end projected freely from opening of the supraomental recess and in some cases the apex of cecum was bent to the left side especially in fasted case. These results in agreement with that denoted by **Habel (1975)** in ruminant and **May (1977)** in sheep.

In X-ray the contrast material began to enter the cecum after 3.5 to 4 hrs after administration, become clear after 6 hrs in the lateral radiograph, the cecum cylindrical or U-shaped structure present under 4th lumbar vertebrae till the pelvic inlet, while in the ventrodorsal view it located entirely in the right side of the abdominal cavity. These result in line with **Abu Zaid (1995)** in goat.

The colon consisted of three parts, ascending, transverse and descending, the ascending colon consisted of proximal, spiral and distal loops. The proximal loop began at the level of 4th lumbar vertebra and directed cranially then caudally till the level 6th lumbar vertebra then cranial to level of 2nd lumbar vertebra. The spiral loop was hemispherical and arranged in coils consisting of centripetal, centrifugal gyri of two and half to three turns of each and central flexure and the distal loop of ascending colon consisted of ventral and dorsal parts. It located in upper third of abdominal cavity under the level of 1st to 4th lumbar vertebrae and connected the spiral loop with transverse colon which lied in in front the cranial mesenteric artery crossing the median plane from right side to the left one and began under the 1st lumbar vertebra, the descending colon began of the left side, inclined to the right at caudal border of the right kidney then to medium plane shortly after form the sigmoid colon at the level of the six lumbar vertebra, similar results obtained by **Habel (1975)** in ruminant and **Badawi et al. (1999)** in goat.

In present work, in X-ray with contrast media, the barium reached in proximal loop of ascending colon at 4 hrs, but complete filling after 6.5 hrs, it appeared in lateral radiograph as U-shape, similar result obtained by **Abu-Zaid (1995)** in goat. The contrast media observed in the spiral colon among 8hrs, the spiral loop was not clearly demonstrated to the superimposition of cecum and rumen and overlapping of its loops over each other, similar results obtained by **Kanwar et al. (1983)** in caprine. While the descending colon was identified by its contents on the fecal pellet that covered by barium after 9 hrs. It located at the roof of the abdominal cavity and run caudally to give the sigmoid colon under the 6th lumbar vertebra.

Liver:

In our present work, the liver of the goat situated in the intrathoracic part of abdominal cavity occupying the right hypochondriac region. It is long axis extending cranioventrally from the level of vertebral end of 13th thoracic rib till the ventral end of 6th intercostal space, similar result obtained by **Awad (2000)** in goat but it began from the middle third of 6th intercostal space instead of ventral end. The site of biopsy of the liver located at the upper fourth 11th or 12th intercostal space in plane low to the tuber coxae .the same result mentioned by **Dyce et al. (2002)**.

Gall bladder:

In present work the gall bladder was pear in shape, it projected 0.5 to 3.5 cm lower than the ventral hepatic border and come in contact with lateral abdominal wall at the ventral of 10th intercostal space. These results are in agreement with that obtained by **Awad (2000)** in goat and **ELgaafary et al. (1979)** in buffalo.

Spleen:

It was oval in shape situated between the dorsal ruminal sac and adjacent to the vertebral column at the caudal border of the upper one fourth of the 10th left rib till the cranial end of transverse process of the 1st lumbar vertebra, similar results observed by **Small wood (1992)** in small ruminant, moreover **Zeskov et al (1976)** in ruminant, observed that spleen visualized from the level of left 10th to 12th ribs. The site of the biopsy of the spleen was at the upper fourth of 12th intercostal space. While **Dyce et al. (2002)** mentioned the site of biopsy was normally made through the upper end of eleventh intercostal space.

Pancreas:

In current work the pancreas was located in the dorsal abdominal cavity, mainly right to median plane under 11th thoracic vertebra till the first lumbar vertebra, 4cm under vertebral column, it consist large right lobe, body and left lobe . the goat had the major pancreatic duct only was present and opened together with bile duct similar result nearly mentioned by **May (1977)** in sheep and **Garratt (1988)** in goat.

Kidney:

The kidney was smooth, round bean shaped and unipapillary organ, the right kidney had fixed position ,due to intimate relation with liver and presented right to median plane which extended from level of 12th intercostal space to transverse processes of 1st or 2nd lumbar vertebra. While the left kidney had variable locations due to loose attachment and affected by the fullness of the rumen. It was presented just caudal to right kidney in most specimens which was pushed entirely to the right of the median plane lied under 2nd, 3rd and 4th lumbar vertebrae. While in fasted goat and immature goat the left kidney presented left to median plane and lied under 3rd, 4th and 5th lumbar vertebra. These positions differed little than mentioned by **Hagri (1967)** in small ruminant where the right kidney presented under first three lumbar vertebrae and left kidney lied under 3rd, 4th and 5th lumbar vertebra.

The right renal artery arose from abdominal aorta at the level of the 2nd lumbar vertebra, while the left renal artery arose at the level of the 3rd lumbar vertebra similar result was obtained by **Tayal et al. (1985)**

Ovary:

The ovary in present work was irregular in shape, the ovaries of non pregnant animals were located craniolateral to middle of the pelvic inlet by 2 cm from the shaft of the ilium and lateral to coiled uterine horn while the ovaries of pregnant animals were located craniolateral to pelvic inlet within the abdominal cavity with the coiled gravid uterine horn by 5 – 6 cm from the pelvic inlet similar result was obtained by both **Shoab (1999)** and **El-Safy (2001)** in the goat.

Uterine tube:

It extends from the tubal extremity of the tip of the ovary to uterine horn, where it opened by a narrow small opening, the uterine tube in non pregnant located at craniolateral to the pelvic inlet, while in pregnant animal located in abdominal cavity cranial to pelvic inlet by 6 – 8 cm., these finding are similar to that recorded by **El-Safy (2001)** in the goat.

Uterus:

The non gravid uterine horns were located partly at the middle of the pelvic inlet in and partly in abdominal cavity, similar result mentioned by **Shoab (1999)** in goat. While the gravid uterine horn was extended till the 2nd or 3rd lumbar vertebra in right abdominal cavity. The uterine body was located at the pelvic cavity followed the uterine horns in non pregnant animals while in pregnant animals, it was located within the abdominal cavity followed the uterine horn with its caudal part at pelvic inlet. The uterine cervix was completely located within the pelvic cavity in non pregnant animals while in the pregnant animal it was rested on the pelvic brim similar results obtained by **El-Safy (2001)** in the goat and **Dyce et al. (2002)** in ruminant.

Urinary bladder:

The position of the bladder was differed greatly according to the state of the fullness as that when it was empty, it wrinkled in appearance and located on the pelvic floor, when was full with urine, it was extended to reach the pelvic brim or abdominal floor, similar finding mentioned by both **Weeren et al (1987)** and **El-Safy (2001)** in goat.

The great vessels within the abdominal cavity:**Celiac artery:**

In present work: the celiac trunk arose from the ventral aspect of the abdominal aorta under the level of the 1st lumbar similar observation mentioned by **Ghoshal (1975)** in sheep, while in goat between 1st and 2nd lumbar vertebra. Celiac artery in the most cases was separated from the cranial mesenteric similar observation recorded by **Karmona et al. (1985)** in sheep and goat.

In present work the celiac trunk divided into three main arteries; hepatic, left gastric and splenic arteries. The hepatic artery gave the right hepatic artery which gave cystic one, and left hepatic artery which gave the left gastric artery in the lesser curvature of the abomasum. The gastroduodenal artery was the terminal branch of hepatic artery which divided into cranial pancreaticoduodenal artery and right gastroepiploic artery which anastomosed with left one at the greater curvature of the abomasum. Similar results in a line with **Ghoshal (1975)** in ox and **May (1977)** in the sheep.

The left gastric artery gave the reticular, left gastroepiploic, omasal and accessory reticular branches, similar observation denoted by **May (1977)** in sheep. The splenic artery was the third branch of celiac artery which gave splenic, right ruminal and left ruminal artery similar result observed by **Horowitz and Venzke (1966)** in goat.

Cranial mesenteric artery:

In present work the cranial mesenteric gave the pancreatic branch, caudal pancreaticoduodenal artery, ileocolic artery, jejunal branches in most specimen the ileocolic artery gave the right colic artery, colic artery and at level of the ileocecolic junction gave the ileal mesenteric branch and cecal branch these results in agreement with **Ghoshal (1975)** in small ruminant and **Levine et al. (1987)** in the bovine; the jejunal arteries originated from the convex surface of the whole length of the cranial mesenteric artery, its number is ranged between 16 – 20 branches. The ileal artery arose from the terminal branch of cranial mesenteric artery which anastomose with ileal mesenteric artery similar to results which described by **May (1977)** in sheep **Levine et al. (1987)** in bovine.

The lymphocenter of abdominal viscera:

1. The celiac lymphocenter.

In present work we found that, the atrial lymph nodes lied on visceral surface of atrium of the rumen behind the cardia, the right ruminal lymph nodes which present in right longitudinal groove and absence of left ruminal lymph nodes, similar result denoted by **Tanudimadja and Ghoshal (1975)** in goat and **Alam Eldin (1984)** in camel.

The omasal lymph nodes, dorsal abomasal lymph node, hepatic lymph nodes and pancreaticoduodenal lymph nodes they recorded in our work, similar observation was mentioned by **Vollmerhaus and Heide (1989)** in goat,

2. The cranial mesenteric lymphocenter

The jejunal lymph nodes were two types elongated and compact jejunal lymph nodes which located inside mesentery. colic lymph nodes scattered on the spiral loop of colon similar observation recorded by **Lowden and Heath (1993)** in sheep while of cecal lymph node present at ileocecolic junction as mentioned by **Lowden and Heath (1993)** in sheep while the **Tanudimadja and Ghoshal (1975)** in goat if found present in mesentery between cecum and ileum.

IV .Surgical approach of the abdomen

Splenectomy:

The site of splenectomy was behind the last rib and may require the resection to the last rib, similar was result obtained by **Deock and Gulinan (1926)** in goat and **Kumar (1998)** in cattle.

Rumenostomy:

The site of rumenostomy was under the space between 2nd and 3rd lumbar transverse processes by 2-3 cm then made incision about 3 cm length,. Similar observation was nearly mentioned by **Ducharme (1990)** in cattle and **Berge and Westhues (1977)** in ruminant.

Rumenotomy:

The site of rumenotomy was under the space between 2nd and 3rd lumbar transverse process by 2-3 cm then make incision about 12-15 cm in length Similar observation mentioned by **Kumar (1998)** in cattle and.

Kidneys:

The site of surgical approach of the right kidney was present caudal to right last rib while the left one present under the 3rd transverse lumbar of the left flank similar result recorded by **Berge and Westhues (1977)** in ruminant.

Abomasum displacement:

The site of incision was parallel to right costal arch and dorsal to cranial superficial epigastric vein and artery similar observation was mentioned by **Kumar (1998)** in ruminant.

Caesarean operation:

In our work the most suitable site for caesarean was presented left at the lower flank under the transverse of 4th lumbar vertebrae similar result was obtained by **El-Safy (2001)** in goat.

SUMMARY

The present work carried out on clinically healthy twenty Egyptian Baladi goats of the different age and weight from both sexes for dissection of the abdomen, X-rays with contrast media, cross-sectional anatomy and C.T. images and surgical approach of the abdomen.

The shape of the abdomen in adult goat was bulged laterally and abdominal floor was curved, while compressed laterally and shallower in immature goat. The abdomen was divided into nine regions which help in topographic anatomy. The dorsal boundary of the paralumbar fossa extended from 2nd to 6th lumbar transverse processes. The scar of the umbilicus presented at the level 1st or 2nd lumbar vertebra.

The ventrolateral abdominal wall consisted of the skin; superficial abdominal fascia which was loose and covered the lateral and ventral abdominal wall. It contained the cutaneous trunci muscle which covered the lateral abdominal wall; cranial and caudal preputial muscle in male and supramammary muscle in female, they rested on the ventral abdominal wall; the abdominal tunic was elastic sheet covering the distal half of the lateral thoracic and abdominal walls; external abdominal muscle arose from the 6th rib to last rib and terminated into the line alba, prepubic tendon and tuber coxae its aponeurosis interwoven with aponeurosis of the internal abdominal oblique muscle in epigastric and mesogastric regions; the internal abdominal oblique muscle was fleshy triangular muscle originated from tuber coxae, inguinal ligament and thoracolumbar fascia and terminated in last rib, linea alba, prepubic tendon; the rectus abdominal muscle consisted of 7 segments and 6 tendinous intersections which gave more strength to muscle and the transverse abdominal muscle, divided into costal and lumbar parts which originated from the costal arch, last four ribs and first five lumbar vertebrae and terminated by thin aponeurosis into xiphoid cartilage and linea alba.

Finally described the inguinal canal with its contents and superficial and deep inguinal ring and described the arterial and venous supply of lateral abdominal wall by cranially and caudal epigastric arteries and veins, cranial and caudal superficial epigastric arteries and veins, musculophrenic artery and vein, dorsal intercostal arteries and veins, dorsal costoabdominal artery and vein and deep circumflex iliac artery and vein. Determination the main nerve supply to the lateral abdominal wall which the costoabdominal, the iliohypogastric and ilioinguinal nerves and the way of the blocking of these nerves which supplied the paralumbar fossa.

The diaphragm was a dome shaped structure between thoracic and abdominal cavities. The midline slope extended from ventral extremity of 6th rib till last thoracic vertebrae. The right and left crura were originated by a large common tendon which attached to ventral longitudinal ligament at the level of 2nd to 6th lumbar vertebra.

Rumen occupied the most of the left portion of abdominal cavity extended from part opposite 8th or 9th rib to the level of tuber coxae. The dorsal ruminal sac come in contact with the left paralumbar fossa and the ventral ruminal sac was enclosed by greater omentum. The

site of auscultation and palpation of the rumen and site of trocarization presented under by 3rd lumbar transverse process. Reticulum was piriform in the shape, was located almost entirely to the left of the median plane, and extended from the 6th rib to 8th ribs and extended to abdominal floor. The area of auscultation of the reticulum located at the ventral end of 6th and 7th intercostal spaces. Omasum presented right median plane which extends from 7th to 9th intercostal spaces which did not contact the right abdominal wall. The abomasum extended from 8th to 12th intercostal spaces or 13th rib, the fundus of abomasum lied centrally in the xiphoid region, the body of abomasum extended on the abdominal floor then inclining to right and extend a little ventral to right costal arch and almost parallel with it and the pyloric part turned to the right caudal to omasum and bend up to lateral wall of abdominal cavity till ended at pylorus.

The greater omentum consisted of the two layers superficial and deep layers and lesser omentum consisted of hepatic gastric and hepatoduodenal ligaments.

The small intestine, consisted of duodenum, jejunum and, ileum. The descending duodenum was the visible part when we made incision in the right flank, jejunum located in the supraomental recess in distal third of peritoneal cavity while the large intestine consisted of cecum, ascending colon, transverse colon and descending colon generally the large intestine occupied the right upper and central portion of the peritoneal cavity.

The rumen, reticulum, omasum, abomasum, small intestine cecum and colon were observed with barium contrast radiograph from its administration of contrast media till 9 hrs at different times

Liver of the goat situated in the intrathoracic part of abdominal cavity occupying the right hypochondriac region extended from 6th intercostal space till 13th rib. The site of biopsy of the liver located at the upper fourth 11th or 12th intercostal spaces. The gall bladder came in contact with right lateral abdominal wall at the ventral 10th intercostal space. The spleen was oval in shape situated in the left side from upper fourth 10th rib till the cranial end of transverse process of the 1st lumbar vertebra. The pancreas located in the dorsal abdominal cavity right to median plane under 11th thoracic vertebra till 1st lumbar vertebra. We determined the position of the kidneys left and right and the left one was wandering kidney.

Determination the position of ovary, uterine horn and uterus in case of non pregnant and in pregnant goats and determine the position of urinary bladder when full with urine and empty.

The computed tomography demonstrated the typical anatomical finding in cross sectional images that are helpful in localization of the abnormalities.

Finally we can determine the surgical approach to abdominal organs of the goat such as site of rumenotomy, splenectomy and approach to left right kidney liver, gall bladder, cecum, abomasum and uterus

The Conclusion

- The shape of abdomen differed according to age and physiological condition. in adult goat, the abdomen was bulged laterally and abdominal floor was curved while compressed laterally and shallower in immature goat
- The weaken part of the abdominal wall that area behind last rib where the external abdominal oblique came in contact with transverse abdominal muscles.
- There were many factors which gave the strength to ventral abdominal wall, the decussation between the aponeurosis of the external and internal abdominal muscles, the split of aponeurosis of the transverse abdominal into two layer which perpendicular to each other, tunica flava was thick and transverse fascia which became strong and distinct to compensate the thinness of the caudal portion of the transverse abdominal muscle.
- In diaphragm, the sternal part was separated from costal part by two fibrous bands which gave strength to the diaphragm against hernia.
- The position of the rumen and reticulum omasum and abomasum changed according to age, feeding condition, and affect of pregnancy.
- The area of auscultation of the rumen present under the 3rd lumbar vertebra in adult goat, while the area of auscultation of reticulum located at the ventral end of 6th the intercostals space.
- The site of liver biopsy was located at the right upper fourth 11th or 12th intercostal spaces or by acute angle at the last intercostal space. While the site of spleen biopsy was presented at the left upper fourth of 12th intercostals space.
- The left kidney was movable according to size of rumen
- The gravid uterine horn was located in the abdominal cavity out side the supraomental recess.
- The X-ray with barium administration will take 9hrs till reach to the rectum.
- The computed tomography of abdomen demonstrated the typical anatomical finding which were appeared in the cross sectional images that are helpful in localization of the abnormalities.
- Determination the sites of the surgical approach to abdominal organs of the goat such as site of rumenotomy, splenectomy and approach to left and right kidneys liver, gall bladder, cecum, abomasum and uterus

REFERENCES

- Abd Elmoien, Z.M.S. (1995)**
Some comparative anatomical studies of the abdominal wall in Carnivores (dog), Small ruminants (goat) and Equines (donkey).
Thesis Ph.D. (Anatomy and Embryology).
Fac. of Vet. Med. Beni. Sweif. Cairo University.
- Abd Elmoneim M.E. (1983):**
The nervi spinalis of camelus dromedarius.
Ph.D. Thesis. Fac. Vet. Med. Assuit Univ. Egypt.
- Abu Zaid R.M.M. (1995)**
Radio and sonographic anatomical studies on the goat.
Ph.D. Thesis, Fac. of Vet. Med. Suez Canal University.
- Abu Zaid, S.M.S. and Imam H.M. (2000):**
Computed tomographic anatomy of the abdomen on the normal wild African Fennec (Fennecus Zereda) SCVMJ. III (1), 2000.
- Ahmad, A.S.I.S. (1999):**
Some Anatomical studies on the thoracic wall of the Egyptian buffalo.
M.V.Sc. Fac. Vet. Med. (Kafr El-Sheikh). Tanta Univ.
- Ahmed, A.k.; M.E. Abdel-Moneim and L.A. Ibrahim (1985):**
Morphological study on the abdominal muscles and inguinal canal of rabbit.
First Int. Conf. App. Sci. Vol. II. Sagazig University.
- Alam Eldin, M.A. (1984):**
Some anatomical studies on the lymphatic system of one humped camel.
Ph.D. Thesis, Fac. Vet. Med. Cairo Univ.
- Al-Safy. M.A. (2001):**
Topographic and applied anatomical studies on the female pelvis of goat.
Thesis M.V.Sc.(Anatomy).
Fac. Vet. Med.Alex. Univ.
- Al-Safy. M.A. (2005):**
Clinical anatomical studies on the thorax of dog.
Thesis Ph.D. (Anatomy)
Fac. Vet. Med.Alex. Univ.
- Anis H. (1977):**
Some anatomical studies on the liver of he buffaloes in Egypt (Bos bubalis L).
Thesis, M.V.Sc. Zagazig Univ.

- Attia, M.M. (1980):**
Anatomical studies on the arterial blood supply of the trunk in the one-humped camel (Camelus dromedarius).
Thesis, M.V.Sc. Fac. Vet. Med. Assuit Univ. Egypt.
- Attia, M.M. (1987):**
Some anatomical studies on the trunks brachiocephalic of Egyptian buffalo (Bos bubalis).
Assiut Vet. Med. J. 18(35)
- Awad, A.S.(2000)**
Gross anatomical study on the liver of the goat.
Thesis, M.V.Sc., Beni-Suief branch (Cairo Univ.).
- Badawi, H; A.K. Ahmed and A.S.M. Saber (1983):**
The branches of the external iliac artery in the one humped camel (Camelus dromedaries).
Assiut Vet. Med. J. Vol.10, No. 20, PP. 21-25.
- Badawi, H; Abd Elmoneim M.E and Ibrahim, I,A(1984)**
Some anatomical studies on the grater omentum, lesser omentum and omental bursa of one humped camel
Assiut Vet. Med. J., Vol.13,NO.25,231-220
- Badawi, H; A.K. Ahmed; N.A. Misk AND F.M. Makady(1985):**
The arterial blood supply and venous drainage of the udder in buffaloes(Bos bubalis).
Assiut Vet. Med. J.,Vol. 14,No 27.
- Badawi, H.; Y.A., Abd-Elrahman; A.O. Salem and A.M. Mohamed (1999):**
Morphological studies on the colon and rectum of some domestic animals with special reference to the end form of the fecal matter.
Assiut Vet. Med. J. Vet. Vol. 40. No 80. P. 32 – 55.
- Beaver, B. (1980):**
Comparative anatomy of the domestic animals.
The Iowa State University press / Ames.
- Berge,e.and M. westhues(1977)**
Veterinary operative surgery.
Medical book company. Denmark
- Bone, J.F. (1979):**
Animal anatomy and physiology.
Reston publishing Inc. Reston Virginia p.p. 161 – 162.
- Cegarra A.J.; Lewis, R.E. (1977):**
Contrast study of the gastrointestinal tract in the goat (Capria hircus).
Am. J. Vet. Res. 38: 1121 – 1128.

- Delahunta A. and Habel R.E. (1986):**
Applied Veterinary Anatomy.
College of Vet. Med. Cornell. Univ. Ithaca, New York.
- Dyce, K.M; Sack, W.O. and Wensing C.J.G. (2002):**
Text book of Veterinary anatomy.
W.B. Saunders Company, Philadelphia , London and Toronto.
- Ducharme, N.G. (1990):**
Surgery of the bovine forestomach compartments.
Veterinary Clinical North America food animal practice Vol. 6, No. 2 July 371 – 397.
- Dekock, G. and Gulinan, J. (1926):**
Splnectomy in the domestic animal and its sequalla with special reference to
anaplasmosis in sheep.
Unicon of South Africa, 11th and 12th reports of director of Vet. Edu. and Res.
- El-Gaafary, M.A.H.; Mobarak, A.M. and Anis H (1979):**
Some anatomical studies on the liver of the buffaloes in Egypt (Bos bubalis L.) I.
topography.
Egypt. Vet. Med. J., 27: 255 – 257.
- El-Gundi E.M. (1971):**
Studies on the lymph nodes of the buffalo in Egypt.
Thesis, M.V.Sc. Fac. Vet. Med. Cairo University.
- El-Hagri, M.A.A. (1967):**
Splanchnology of domestic animals 1st public organization for books and scientific
publication. Cairo Univ.
- Etemadi, A.A. (1966):**
Diaphragm and os diaphragmaticum in camelus dromedarius.
Acta anat. 66: 551-560.
- Evans; H. E. and Delahunta A. (1988):**
Miller's Guide to the dissection of the dog.
3rd Edition, W.B. Saunders Company. London and Toronto.
- Garrett, P.D. (1988):**
Guide to ruminant anatomy based on the dissection of the goat. Low state university
press AMES.
- Getty, R. (1975):**
Ruminant mycology in Sisson and Grossman's the anatomy of the domestic animals.
Rev. By .Getty Vol. I. 5th Ed. W.B. Saunders Company, Philadelphia, London and
Toronto.

- Ghoshal, N.G. (1975):**
Caprine heart and arteries in Sisson and Grossman's the anatomy of Domestic animals by Rev. By .Getty Vol. I. 5th Ed. W.B. Saunders Company, Philadelphia, London and Toronto.
- Ghoshal; N. G.; T. Koch and P. Popesko (1981)**
The venous drainage of the domestic animals.
W.B. Saunders Company, Philadelphia, London and Toronto and Sydney.
- Green, E.D. and Baker, C. (1996):**
The surface morphology of the omasum of the African goat.
Journal of the South Africa Veterinary Association 67 (3): 117 – 122.
- Habel, R. E (1975):**
Ruminant digestive system in Sisson and Grossman's the anatomy of the domestic animals. Rev. By .Getty Vol. I. 5th Ed. W.B. Saunders Company, Philadelphia, London and Toronto.
- Habel, R. E. and Klaus, B. (1992):**
Anatomy of the prepubic tendon in the horse, cow, sheep, goat and dog.
Am. J.V. Res. November. Vol. L 53, No. 11, 2183-2195
- Hifny A., A.K. Ahmed and Ibrahim (1981):**
Some anatomical studies on the external iliac artery in mule.
J. Egypt. Vet. Med. Assoc., Vol .41, No 3 .77-82
- Hifny A., A.K. Ahmed and M.A. Attia (1982):**
Some anatomical studies on the internal thoracic artery of the one humped camel camelus dromedaries.
Assiut Vet. Med. J. Vol. 10, No. 19 P.P. 2-6.
- Hifny A., A.K. Ahmed and M.A. Attia (1984):**
Aorta thoracica of the one-humped camel (Camelus dromedarius).
Assuit Vet. Med. J., Vol.11, No.22, P.P. 8:12
- Hifny, A.; A.K.Ahmed and I.A.Ibrahium (1984):**
Course and distrubation of A. thoracic interna in mule (Equus hinnus).
Assuit Vet. Med. J., Vol. 12, No. 23 P.P. 16-21.
- Hifny, A.; A.K.Ahmed and I.A.Ibrahium (1985):**
Topography and morphology of the stomach of the camel.
Assuit Vet. Med. J. Vol. 15 No. 29.p.p. 45 – 54.
- Horowitz, A. and W.G. Venzke(1966):**
Distribution of blood vessels to the post diaphragmatic digestive tract of the goat.
Am. J. Vet. Res. 27:1293 – 1315.

- Kanware, M.S.; Chandna, I.S.; Singh A.P.; Daphiyn, Z.S. and Sharma D.N. (1983):**
Contrast radiography of gastrointestinal tract in caprine.
Indian J. Anim. Sci. 53: 7, 724 – 732.
- Karmona K.H. and G.Kavachev (1985):**
Variability of the celiac artery and its branched in sheep.
Vet. Med. Nauki 22 (4): 31-37.
- Kassem, M. (1983)**
Studies on the healing of hysterotomy wounds after caesarean section in Egyptian goat.
Thesis Ph.D. (surgery) Fac. Vet. Med. Alex. Univ
- Kumar, A (1998):**
Veterinary surgical techniques.
Vikas publishing house. Pvt LTD, India
- Levine, S.A.; Donald F.S.; Norman J. and Wilsman, D.S. (1987):**
Arterial and venous supply to bovine jejunum and proximal part of ileum.
Am. J. Vet. Res. Vol. 48 No. 8.
Tayal, R.; Chandna, I.S
- Linzell J.L. (1959):**
The innervations of the mammary gland in the sheep and goat with observation on the lumbosacral autonomic nerves.
Quart. J. Exp. Physiol. Vol. 44, P.P. 160 – 176.
- Lowden, s. and Heath, T. (1993)**
Lymphatic drainage from the distal small intestine in sheep.
J.anat.183, p.p. 13 - 20
- May, N.D.S. (1977):**
The anatomy of the sheep.
3rd Ed. University of queens land press Brishane, Australis.
- Nickel R.; Schummer A. and Seiferle, E. (1973):**
The viscera of domestic animals.
Translation and revision by Sack, w.o
Verlag, Papularey Berlin and Hamburg.
- Nickel, R.; Schummer A., and Seiferle E. (1986):**
The anatomy of the domestic animals, Vol. I. locomotor system the domestic animals.
Verlag Papularey. Berlin, Hamburg.

- Shoaib M.M. (1999)**
Comparative morphological studies on the female genital organs of ruminants in Egypt.
M.V.SC. thesis, Fac. Vet. Med. Alex. Univ.
- Sisson, S. (1975):**
Equine mycology in Sisson and Grossman's the anatomy of the domestic animals. Rev. By .Getty Vol. I. 5th Ed. W.B. Saunders Company, Philadelphia, London and Toronto.
- Small Wood, J.E. (1992):**
A Guide tour of Veterinary Anatomy. W.B. Saunders Company Philadelphia, London and Toronto.
- Smuts, M.S. and A.J. Bezidenhout (1987):**
Anatomy of the dromedary.
Clareduson press Oxford.
- Solanki, H.J. and D.V. Sharma (1964):**
Presence of a heterotopic bone in tendinous center of the diaphragm of the camel (osphrenici):
Animal Science, Udoipur, Bikaner.
- Sweeny C.M. (1988):**
A comparative study of the anatomy of the omasum in domesticated ruminants.
Aust. Vet. J. 65; 205-207
- Tayal R. ; Chandna, I.S; Singh, A.P and Peshin, P.K (1985).**
Selective Renal Angiography in goat.
Indian, J. of animal Sci. (55) 2: 98 – 101
- Tanudimadja, K and N.G. Ghoshal (1975):**
Lymphatic system in caprine in Sisson and Grossman's the anatomy of Domestic animals by R. Getty Vol. I. the 5th ed. W.B. Saunders Company, Philadelphia, London and Toronto.
- Tomposet, D.H. and C. Wakeley (1970):**
Anatomical techniques.
E & S. Living ston. LTd Edinburgh and London.
- Vollmerhaus B. (1981):**
Systema lymphaticum in Nickel ,Schummer and Seiferle
Lerbuch der anatomic der haustierle , Vol. 3
Verlag, Papularey Berlin and Hamburg.
- Vollmerhaus B. and Heide, R (1989)**
The lymph node of the stomach of sheep (ovis aries) and goat (capra hircus)

Anat. Histol. Embryol. 18 , 374-380

Weeren, P.R. ; Klein , W.R and Voorheut, G. (1987).

Urolithiasis in small ruminants.

Retrospective evaluation of urothrotomy.

Vet., Quarterly, Vol.9.No. 1, 76 -83

Yadm, Z.A. (1990)

Some macromorphological observation of the udder of the she donkey

Alex. J. Vet. Sci ,vol.6,No 1

Yadm, Z.A. and A.M. Erasha (1990)

Comparative morphological study on the abdominal musculature of the rabbit and cat

Alex. J. Vet. Sci ,vol.6,No 1

Yossef, G.A.E. (1987)

Some anatomical studies on the arteries of the thoracic cavity of the goat.

M.V.SC. thesis, Zagazig, Univ. Benha.

Zeskov, B.; Petrovic, B. and Dragnovic, B (1976).

Retroperitoneal visualization of abdominal organs in domestic animals .

AVRS. 17, 23-30

Cited after Abu Zaid (1995)

الملخص العربى

الأقتراب التشريحي الجراحى للبطن فى الماعز

أجريت هذه الدراسة على عشرون من الماعز مختلفة الأعمار و الجنس لأتمام :

١. تشريح البطن .
٢. أشعة أكس .
٣. الأشعة المقطعية .
٤. التشريح المقطعى .
٥. الأقتراب الجراحى .

- التشريح لجدار البطن فى الماعز الذى يحتوى على :
 ١. الرداء الأصفر البطنى الذى يتكون من الياف مرنة .
 ٢. العضله الجلدية الجذعية تغطى البطن و الجدار الصدرى الخارجى و تنفصل كل منهما من الجهه الظهرية بمسافة واضحة .
 ٣. تم وصف كل من العضله المنحرفه البطنية الخارجية و الداخلية . و كذلك العضله المستقيمة البطنية التى تنقسم بواسطه قواطع عرضيه و كذلك تم وصف العضله المستعرضه البطنية .
 ٤. القناة الأربية فى أناث الماعز تحتوى على الأوعيه الأستحيائية الخارجيه و العصب التناسلى . و تحتوى فى الذكور على الحبل المنوى الذى يحتوى على الأوعيه الدموية و الأعصاب التى تغذى الخصيه .
 ٥. وصف كل الشرايين و الأوردة التى تغذى جدار البطن .
 ٦. يتغذى جدار البطن من الأعصاب بين الضلعيه و على الأعصاب القطنية الشوكيه الأول و الثانى .
- التشريح الطبوغرافى للحجاب الحاجز و أجزاءه التشريحيه و أماكن التصاقه بالضلوع و ذلك لتحديد مخرج التجويف الصدرى .
- التشريح الطبوغرافى للكرش فى الشبكية الورقيه و المنفحه فى الماعز البالغه و غير البالغه و العشار و الماعز الصائمه و إظهار الأختلاف الطبوغرافى فى كل حالة و تحديد أماكنها .
- التشريح الطبوغرافى للأمعاء الدقيقة و الغليظه وجد أن الأمعاء الدقيقة تشغل الثلث الأسفل الأيمن من تجويف البطن و أن الأمعاء الغليظه تحتل الثلثين الأوسط و الأعلى الأيمن من تجويف البطن .
- تم تأكيد التشريح الطبوغرافى للجهاز الهضمى بأستخدام أشعة إكس بأستخدام الباريم الذى يستغرق حوالى تسع ساعات حتى يصل للقولون الهابط .

- التشريح الطبوغرافى للكبد و المراره و الطحال و البنكرياس و الكلى وكذلك أماكن أخذ العينات من الكبد و الطحال و الحقن فى المراره .
- التشريح الطبوغرافى للمبيض و الرحم فى حالتى الأناث العشار و الغير عشار و علاقتها بالتجويف البطنى .
- تشريح الطبوغرافى للمثانة البولية و علاقتها بالأعضاء المجاوره .
- دراسة الشرايين المغذيه للكروش و الشبكية و الورقيه و المنفخه و الكبد و الطحال و البنكرياس و الأثنى عشر و الشريان المغذيه للأمعاء الدقيقة و الغليظه .
- تم دراسة العقد الليمفاويه داخل البطن .
- تم عمل التشريح المقطعى العيانى لمنطقة التجويف البطنى فى حالة الماعز البالغه و غير البالغه و ملاحظه التغير الطبوغرافى للأعضاء الموجوده داخل البطن .
- أوضحت الدراسه بالأشعه المقطعيةقدرة تصويريه دقيقه للتركيبات التشريحيه للأعضاء المختلفه داخل البطن .
- تحديد أماكن الأقتراب الجراحى للأعضاء المختلفه فى البطن و تحديد أماكن الفتح فى جدار البطن .

لجنة الأشراف .



أ.د/ السيد عيسى عنانى

أستاذ ورئيس قسم التشريح و علم الأجنه كلية الطب البيطرى جامعة
الأسكندرية



أ.د/ محمد السيد أمين سلامه

أستاذ التشريح و علم الأجنه كلية الطب البيطرى جامعة الأسكندرية



أ.د/ رأفت محمد أحمد البقرى

أستاذ التشريح و علم الأجنه كلية الطب البيطرى جامعة الأسكندرية

الإقتراب التشريحي الجراحي للبطن في الماعز

مقدمه من

السيد طاب / سمير أحمد عوض الجندي

للحصول على درجة

دكتور الفلسفه فى العلوم الطبيه البيطريه

التشريح

لجنة المناقشة والحكم على الرسالة .

موافقون

أ.د/ عبد الله حفتى طه

أستاذ التشريح المتفرغ بكلية الطب البيطرى جامعة أسسوط

أ.د/ على عبد القادر طلبه

أستاذ التشريح وعميد كلية الطب البيطرى جامعة كفر الشيخ

أ.د/ السيد عيسى عنانى

أستاذ ورئيس قسم التشريح وعلم الأجنه كلية الطب البيطرى جامعة

الأسكندرية (مشرف)

أ.د/ محمد السيد أمين سلامه

أستاذ التشريح وعلم الأجنه كلية الطب البيطرى جامعة الأسكندرية


(مشرف)

أ.د/ رأفت محمد أحمد البقرى

أستاذ التشريح وعلم الأجنه كلية الطب البيطرى جامعة الأسكندرية

(مشرف)

التاريخ ٢٠٠٧/٥/١٦



٥٣-

الإقتراب التشريحي الجراحي للبطن فى الماعز

رسالة علمية

مقدمه الى الدراسات العليا بكلية الطب البيطرى - جامعة الاسكندرية

إستيفاء للدراسات المقرره للحصول على درجة

دكتورا الفلسفه فى العلوم الطبية البيطرية

فى

التشريح

مقدمه من

ط.ب / سمير أحمد عوض الجندى

مايو (٢٠٠٧)